

## Case Report

# *Hiccups Are a Rare Symptom of Supraventricular Tachycardia: Case Report*

Amir Hosein Khandan<sup>1</sup>, MD; Asghar Mohamadi\*<sup>2</sup>, MS

### ABSTRACT

Paroxysmal supraventricular tachycardia (PSVT) is one of the most common arrhythmias, and it occurs in the general population with a good prognosis. PSVT occurs in all age groups, with an incidence rate of approximately 1–3 cases per 1000 persons. We describe a patient presenting with PSVT and a complaint of hiccups. (*Iranian Heart Journal 2020; 21(1): 119-121*)

**KEYWORDS:** Paroxysmal supraventricular tachycardia, Hiccup

<sup>1</sup> Lorestan University of Medical Sciences, Khorramabad, IR Iran.

<sup>2</sup> Cardiovascular Research Center, Shahid Rahimi Hospital, Lorestan University of Medical Sciences, Khorramabad, IR Iran.

\*Corresponding Author: Asghar Mohamadi, MS; Lorestan University of Medical Sciences, Khorramabad, IR Iran.

Email: asgharheart@gmail.com

Tel: 09106042707

Received: March 6, 2019

Accepted: June 10, 2019

Paroxysmal supraventricular tachycardia (PSVT) is defined as a sudden increase in heart rate that ends suddenly. PSVT has different types of electrophysiologic patterns such as atrial tachycardia, atrioventricular (AV) nodal reentry, and atrioventricular reentrant tachycardia (AVRT).<sup>1</sup> The most common symptom of this arrhythmia is palpitation and other symptoms include shortness of breath, chest discomfort, weakness and fatigue, lightheadedness, dizziness, and syncope.<sup>2</sup> We herein describe a 45-year-old man with PSVT who presented to the emergency department with a complaint of hiccups.

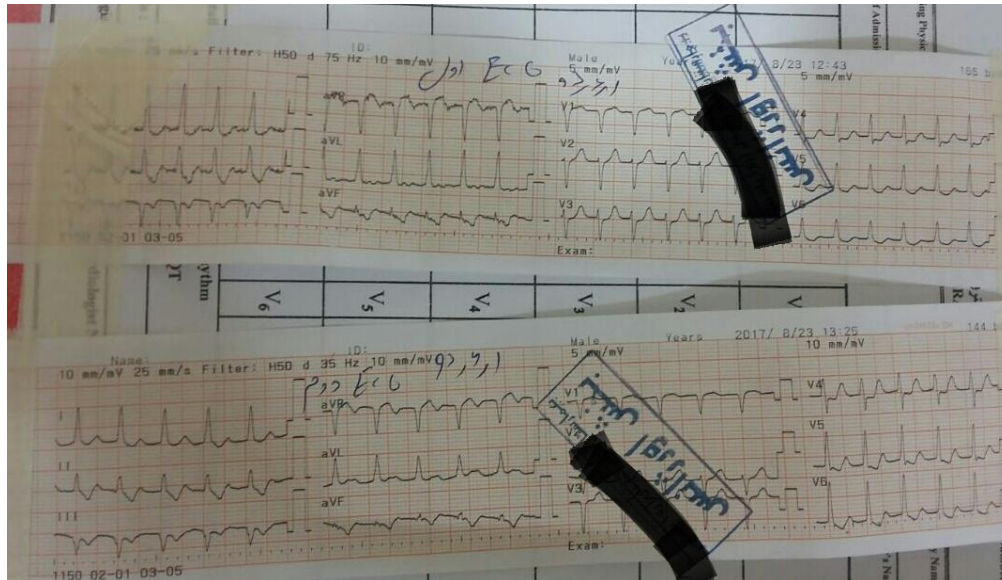
### Case Report

A 45-year-old man who had a history of hypertension and cigarette smoking presented to the emergency department with a complaint of hiccups. On physical

examinations, the patient had blood pressure of 120/80 mm Hg, heart rate of 160 bpm, respiratory rate of 18, and body temperature of 37 °C. Cardiac examinations were normal. The patient did not mention a history of heart disease and did not take any medication. The reason for his referral to the hospital was a hiccup of 2 hours' duration. He was immediately monitored, and an ECG was taken. The ECG revealed a regular narrow complex tachycardia (Fig. 1). Given a retrograde P-wave just after the QRS, an AVNRT rhythm was suggested as the first differential diagnosis. However, other diagnoses such as an orthodromic AVRT rhythm could not be ruled out definitively and a definitive diagnosis required electrophysiology study. The patient refused to undergo an electrophysiology study, forcing the treating physician to interpret the rhythm based on the surface ECG. Adenosine (6 mg intravenously) was rapidly

injected, after which the patient suffered dyspnea. The dyspnea was resolved after 1 hour, and the arrhythmia was converted into

the sinus rhythm. Moreover, the hiccup disappeared after the termination of the tachyarrhythmia.



**Figure 1.** ECG recorded immediately after the presentation of the patient to the emergency department. Given the retrograde P-wave just after the QRS, an atrioventricular reentrant tachycardia rhythm was proposed as the first differential diagnosis.

## DISCUSSION

PSVT has several symptoms that include palpitations, shortness of breath, chest discomfort, weakness and fatigue, lightheadedness, dizziness, and syncope.<sup>2</sup> We herein reported a rare symptom of arrhythmia that our patient suffered due to a hiccup. The symptoms lasted for several hours, thus the patient was forced to seek treatment. A hiccup is an involuntary contraction of the diaphragm, followed by laryngeal closure.<sup>3</sup> Many disorders can cause hiccups including stroke, tumors, herpes infection, gastroesophageal reflux disease, various drugs (eg, anti-Parkinsonism drugs, anesthetic agents, and steroids), and chemotherapies.<sup>4</sup> Suh et al<sup>5</sup> reported a case in which hiccups were associated with bradycardia and suggested that the Valsalva maneuver had enhanced

the parasympathetic tone and caused the hiccup. Hiccups can also be a sign of more serious problems in the heart. For example, hiccups after cardiac pacemakers or implantable cardioverter-defibrillator placement are probably a sign of lead perforation.<sup>7</sup> Hiccups can also be a sign of the pathological activation of the arc reflex, and some disorders in the heart such as myocardial ischemia and the inflammation of the pericardium can lead to hiccups. In a case report, myocardial ischemia generated hiccups, which were treated with coronary angioplasty.<sup>6</sup> The existing literature is devoid of an explanation about the mechanism of hiccups secondary to PSVT; nonetheless, a possible mechanism that may be involved is myocardial ischemia that occurs during tachyarrhythmias and induces hiccups. Interestingly, in our patient, although the hiccup increased the vagal tone,

it could not terminate the PSVT and the authors did not have a clear explanation for this phenomenon.

The goal of this case report is to introduce a sign of arrhythmia to emergency department physicians and cardiologists in order that they will be aware of this rare symptom of arrhythmia and suspect PSVT in patients who refer to the emergency department with this complaint.

### REFERENCES

1. Kadish A, Passman R. Mechanisms and management of paroxysmal supraventricular tachycardia. *Cardiology in review*. 1999;7(5):254-64.
2. Al-Zaiti SS, Magdic KS. Paroxysmal Supraventricular Tachycardia. *Critical Care Nursing Clinics*. 2016;28(3):309-16.
3. Krysiak W, Szabowski S, Stepień M, Krzywkowska K, Krzywkowski A, Marciniak P. Hiccups as a myocardial ischemia symptom. *Polskie Archiwum Medycyny Wewnętrznej*. 2008;118(3):148.
4. Chang F-Y, Lu C-L. Hiccup: mystery, nature and treatment. *Journal of neurogastroenterology and motility*. 2012;18(2):123.
5. Suh WM, Krishnan SC. Violent hiccups: an infrequent cause of bradyarrhythmias. *Western Journal of Emergency Medicine*. 2009;10(3):176.
6. Saarel EV, Hinkle K, Etheridge SP. Serious case of the hiccups. *HeartRhythm Case Reports*. 2015;1(4):159.