

Case Report

Successful Surgery in Acute Type A Dissection in a Patient With COVID-19

Mehrdad Jafari Fesharaki^{1*}, MD; Zahra Ansariaval², MD; Azin Alizadehasl³, MD

ABSTRACT

Coronaviruses are a large family of RNA viruses, the most pathogenic of which are SARS-CoV, MERS-CoV, and the newest type, SARS-CoV-2.¹ Since the start of the recent spread of the coronavirus in the world, the number of patients with cardiovascular diseases referring to emergency departments has decreased due to various reasons. However, many of the patients who do refer to emergency departments may have the complications of coronavirus disease 2019 (COVID-19). We herein describe a patient who was admitted with an acute coronary syndrome after having developed the symptoms of coronavirus and was eventually diagnosed with acute Type A dissection. (*Iranian Heart Journal 2020; 21(4): 124-128*)

KEYWORDS: Coronavirus, COVID-19, Dissection

¹ Department of Cardiology, School of Medicine, Shahid Beheshti University of Medical Sciences, Tehran, IR Iran.

² Clinical Research Development Center, Shahid Modarres Educational hospital, Shahid Beheshti University of Medical Sciences, Tehran, IR Iran.

³ Cardio-Oncology Research Center, Rajaie Cardiovascular Medical and Research Center, Iran University of Medical Sciences, Tehran, IR Iran.

***Corresponding Author:** Mehrdad Jafari Fesharaki, MD; Department of Cardiology, School of Medicine, Shahid Beheshti University of Medical Sciences, Tehran, IR Iran.

Email: Mehrjfm@yahoo.com

Tel: +989122159074

Received: August 6, 2020

Accepted: August 22, 2020

Recent studies have shown that since the start of the recent spread of the coronavirus around the globe, the number of patients hospitalized with acute cardiovascular problems has decreased significantly.² There are several reasons for this drop in figures, the most notable of which are social distancing, quarantine, and fear of contracting the virus in hospitals. However, many patients who are hospitalized with coronavirus disease 2019 (COVID-19) are older and have 1 or more underlying conditions, including heart problems.³ Herein, we describe a middle-aged patient with SARS-CoV-2 who presented with severe chest pains shortly after the completion of viral treatment and underwent

surgery with a diagnosis of acute aortic dissection.

Case Presentation

A 43-year-old man, who had no notable medical history, referred to the emergency department with severe chest discomfort. Except for a family history of heart problems in his mother, the patient did not mention any other coronary risk factors. Three weeks earlier, he had referred to another center with fevers and coughs and received treatment on an outpatient basis for a coronavirus infection.

At the time of admission, the patient's vital signs were stable, and he had normal pulses in his extremities. He was hospitalized with

a diagnosis of an acute coronary syndrome. Computed tomography (CT) scanning showed no evidence of pulmonary infection (Fig. 1). During his hospitalization, the patient's chest pains continued; nonetheless, he had no changes in his electrocardiograms, nor did he exhibit any rise in his cardiac enzymes. Transthoracic echocardiography revealed normal left ventricular function and valves. Additionally, dilation was observed in the ascending aorta, with a flap of dissection from the root of the aorta to the arch, accompanied by severe secondary aortic valve insufficiency (Fig. 2 & Movie 1). Based on the patient's recent history of the coronavirus, a polymerase chain reaction (PCR) test with a nasopharyngeal sample was done; the result was positive. Taking into account the clinical condition of the patient and the possibility of exposure to high aerosols during transesophageal echocardiography, we opted for the CT angiography of the chest and the abdomen as the next diagnostic method and found aortic root dilation (57 mm) with the dissection flap commencing from the right Valsalva sinus (right coronary artery involvement)

and extending to the ascending aorta, the arch, the descending thoracic aorta, and ultimately the renal arteries (Fig. 3 & 4).

The patient was immediately transferred to the operating room, where he underwent the Bentall surgery with the repair of the right coronary artery. Fortunately, after 24 hours, he was extubated with stable hemodynamics (Fig. 5).

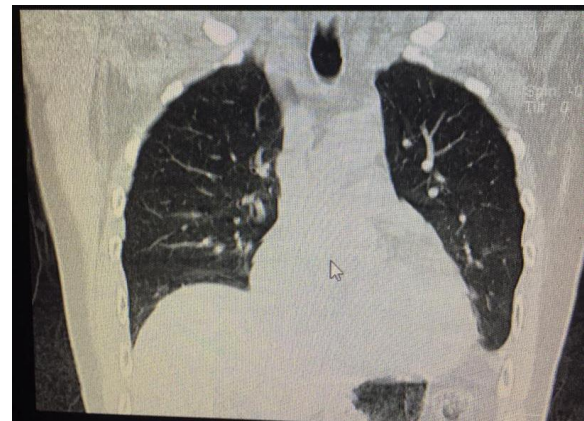


Figure 1. Lung computed tomography shows no evidence of active COVID-19 infection.

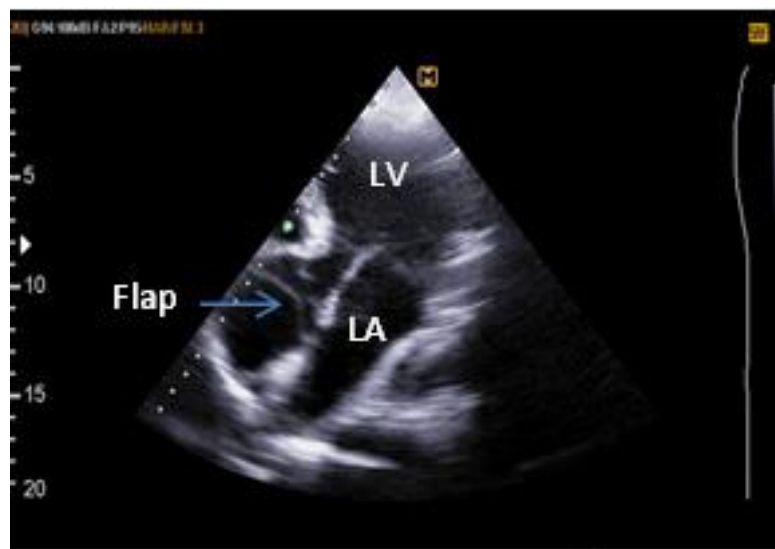


Figure 2. Transthoracic echocardiography (apical view) shows the dissection flap.

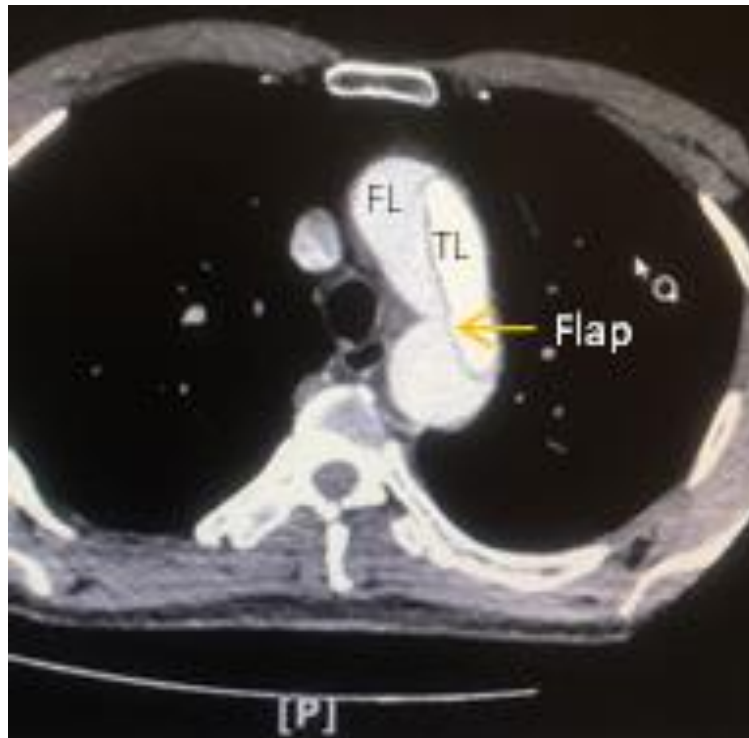


Figure 3. Chest computed tomography with contrast injection shows the dissection flap.
FL, False lumen; TL, True lumen

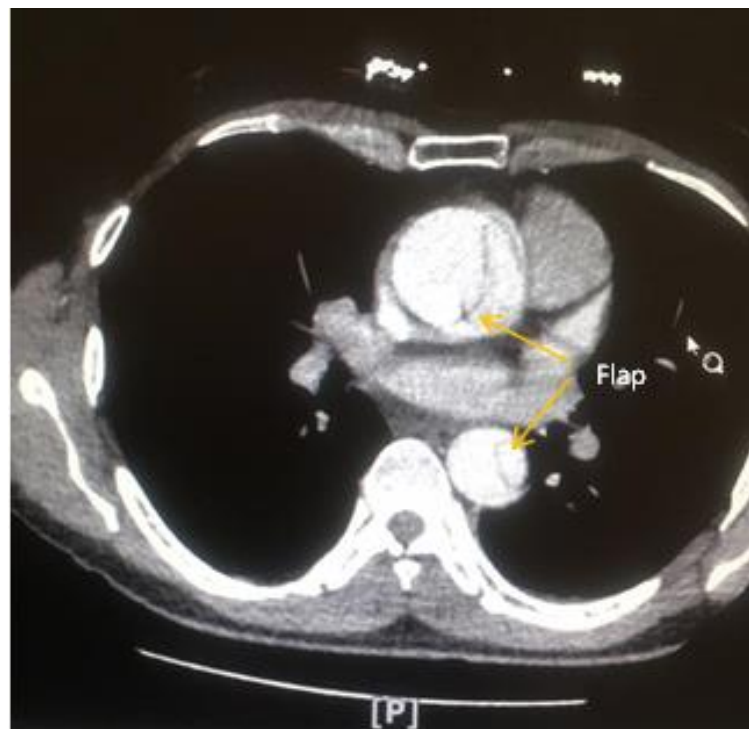

Figure 4. Dissection flap is illustrated in the ascending and descending aortae.

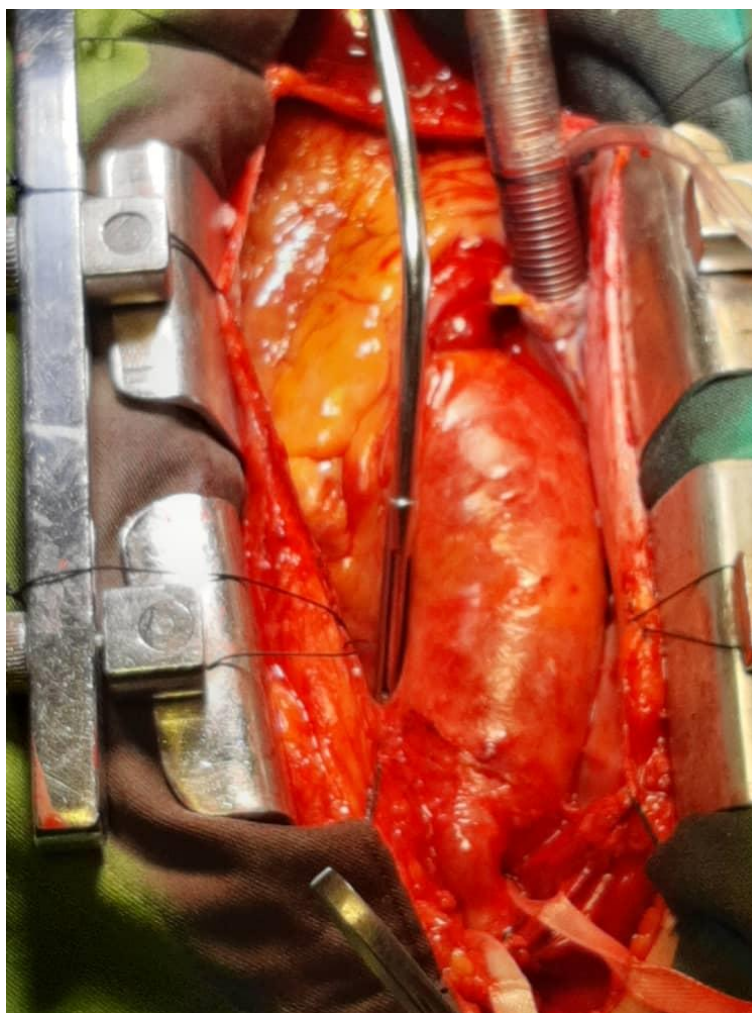


Figure 5. Aneurysmal ascending aorta is demonstrated herein.

DISCUSSION

With the spread of the coronavirus in the world, extensive studies have been conducted on its prevalence in patients with heart problems. In an analysis of 6 large studies on 1527 patients, the prevalence of cardiocerebrovascular diseases was 16.4%. At least 8% of patients suffering from COVID-19 had acute cardiac damage.⁴

Various mechanisms have been proposed as the cause of this damage in patients with COVID-19; they include systemic inflammation, pro-coagulant state, and the rupture of atherosclerotic plaques.⁵

Aortic syndromes, including aortic dissection, intramural hematoma, and

penetrating ulcer with an incidence of 3.5% per 100 000, are not uncommon.⁶ Indeed, some studies have even reported that its incidence has been on the rise.⁷

Reports of acute aortic syndromes in patients with the coronavirus are very limited,⁸ and little is known about its prevalence in COVID-19. Generally, any delay in diagnosis and treatment is associated with an increase in mortality; and for each hour of delay, its mortality rate increases by 1%.⁹

The American College of Surgeons has published a new instruction on how to perform surgical operations during the outbreak of the coronavirus. It recommends delaying elective procedures to prevent the

spread of the coronavirus; still, it does not recommend any delays in emergency surgery.¹⁰

In our patient, the association between the aortic dissection and the recent coronavirus infection is unclear. It is important to consider an acute aortic dissection as a differential diagnosis of acute coronary syndromes. The most common age for aortic dissection is about 70 years¹¹; however, in a middle-aged person with severe chest pains and no underlying evidence of atherosclerosis or electrocardiographic changes, it should be considered a differential diagnosis. The successful surgery in our patient with his recent history of COVID-19 indicates that there should be no delay in treating patients with acute aortic dissection, especially in asymptomatic patients who are recovering from this infectious disease. Indubitably, this scenario requires the provision of sufficient protection to medical staff and the preparation of a separate operating room and ward.

REFERENCES

1. Weiss, S.R. and S. Navas-Martin, Coronavirus pathogenesis and the emerging pathogen severe acute respiratory syndrome coronavirus. *Microbiol Mol Biol Rev*, 2005. 69(4): p. 635-64.
2. Metzler, B., et al., Decline of acute coronary syndrome admissions in Austria since the outbreak of COVID-19: the pandemic response causes cardiac collateral damage. *Eur Heart J*, 2020. 16(5820829).
3. Garg, S., et al., Hospitalization Rates and Characteristics of Patients Hospitalized with Laboratory-Confirmed Coronavirus Disease 2019 - COVID-NET, 14 States, March 1-30, 2020: *MMWR Morb Mortal Wkly Rep*. 2020 Apr 17;69(15):458-464. doi: 10.15585/mmwr.mm6915e3.
4. Li, B., et al., Prevalence and impact of cardiovascular metabolic diseases on COVID-19 in China. *Clin Res Cardiol*, 2020. 109(5): p. 531-538.
5. Xiong, T.Y., et al., Coronaviruses and the cardiovascular system: acute and long-term implications. *Eur Heart J*, 2020. 18(5809453).
6. Clouse, W.D., et al., Acute aortic dissection: population-based incidence compared with degenerative aortic aneurysm rupture. *Mayo Clin Proc*, 2004. 79(2): p. 176-80.
7. Olsson, C., et al., Thoracic aortic aneurysm and dissection: increasing prevalence and improved outcomes reported in a nationwide population-based study of more than 14,000 cases from 1987 to 2002. *Circulation*, 2006. 114(24): p. 2611-8.
8. Fukuhara, S., C.M. Rosati, and S. El-Dalati, Acute Type A Aortic Dissection during COVID-19 Outbreak: *Ann Thorac Surg*. 2020 Apr 22. pii: S0003-4975(20)30594-4. doi: 10.1016/j.athoracsur.2020.04.008.
9. DeMartino, R.R., et al., Population-Based Assessment of the Incidence of Aortic Dissection, Intramural Hematoma, and Penetrating Ulcer, and Its Associated Mortality From 1995 to 2015. *Circ Cardiovasc Qual Outcomes*, 2018. 11(8): p. 004689.
10. Fong, Z.V., et al., Practical Implications of Novel Coronavirus COVID-19 on Hospital Operations, Board Certification, and Medical Education in Surgery in the USA. *J Gastrointest Surg*, 2020. 20(10): p. 020-04596.
11. Howard, D.P., et al., Incidence, risk factors, outcome and projected future burden of acute aortic dissection. *Ann Cardiothorac Surg*, 2014. 3(3): p. 278-84.