

Original Article

Gated SPECT Phase Analysis of Abnormal Left Ventricular Wall Motion Polar Maps in Patients With Normal Perfusion, Normal Global Function, and Low Pretest Probability of Ischemic Heart Disease

Feridoon Rastgou¹, MD; Ahmad Bitarafan-Rajabi², PhD; Omid Inanloo¹, MD; Hadi Malek¹, MD; Nahid Yaghoobi¹, MD; Leila Hassanzadeh³, PhD; Fahimeh Rayegan¹, MD; Seyed Hassan Firoozabady^{1*}, MD

ABSTRACT

Background: One of the probable reasons for wall motion polar map abnormalities is left ventricular (LV) dyssynchrony. The objective of this study was to evaluate LV dyssynchrony via the phase analysis on myocardial perfusion imaging (MPI) in patients with a low pretest probability of ischemic heart disease (IHD) and normal electrocardiography (ECG)-gated MPI as the possible contributor to LV regional wall motion polar map abnormalities.

Methods: A total of 181 patients with a low likelihood of IHD, normal MPI, a normal global function, and a normal global ejection fraction were divided into 2 groups: Group A: 81 patients with abnormal regional wall motion and Group B: 100 patients with normal wall motion polar maps. Dyssynchrony in the LV wall was assessed in terms of the phase analysis indices of entropy, the phase histogram bandwidth, and the phase standard deviation quantified by quantitative gated SPECT software, and the results for both groups were compared.

Results: The mean entropy values in the LV anterior, lateral, inferior, and particularly septal walls ($P < 0.0001$), as well as the mean entropy value in the LV apical wall ($P = 0.030$), in Group A were significantly higher than those in Group B. Moreover, the phase histogram bandwidth and the phase standard deviation were considerably higher in Group A than in Group B in all LV walls ($P < 0.0001$), except the LV apical wall ($P = 0.063$ and $P = 0.036$) respectively.

Conclusions: Assessment of the phase analysis indices for LV dyssynchrony could be used in patients with a low probability of IHD, a normal LV perfusion, and abnormal wall motion polar maps as a complementary tool for the interpreting physician. (*Iranian Heart Journal 2020; 21(4): 67-75*)

KEYWORDS: Left ventricle, Dyssynchrony, Phase analysis, Phase histogram bandwidth, Phase standard deviation, Myocardial perfusion imaging

¹ Rajaie Cardiovascular Medical and Research Center, Iran University of Medical Sciences, Tehran, IR Iran.

² Cardiovascular Intervention Research Center, Rajaie Cardiovascular Medical and Research Center, Iran University of Medical Sciences, Tehran, IR Iran.

³ Department of Nuclear Medicine, School of Medicine, Rajaie Cardiovascular, Medical & Research Center, Iran University of Medical Sciences, Tehran, IR Iran.

*Corresponding Author: Seyed Hassan Firoozabady, MD; Rajaie Cardiovascular Medical and Research Center, Iran University of Medical Sciences, Tehran, IR Iran.

Email: shfirouz@gmail.com

Tel : +989121119821 - +982122048173

Received: October 20, 2019

Accepted: January 16, 2020

Electrocardiography (ECG)-gated single-photon emission computed tomography (SPECT) myocardial perfusion imaging (MPI) is a method for the assessment of the global and regional wall motions, function, and synchronous contractions of the left ventricle (LV).^{1,2} Left ventricular dyssynchrony (LVD), which can be measured by gated SPECT, is also used as an index for LV myocardial perfusion and function simultaneously.^{3,4} Not only are the indices derived by SPECT MPI for mechanical dyssynchrony reproducible,⁵ applicable to retrospective data, and widely available but also they have been noted as an alternative to 2D echocardiography, which is currently used to measure interventricular dyssynchrony. The measurement of LVD via the phase analysis of SPECT MPI indices provides 3D data on LV function. Patients who have LV dysfunction or conduction abnormalities show higher mechanical dyssynchrony indices.⁶⁻⁸ Another advantage of LVD measurement is its predictive value for patients who receive cardiac resynchronization therapy. Therefore, an assessment of LVD is necessary for a more accurate selection of patients who would respond to cardiac resynchronization therapy more consistently.⁹⁻¹²

Wall motion polar maps can also be assessed with respect to LVD in a precise manner.^{11,13-16} While several studies have used LVD and suggested that abnormalities in the dyssynchrony indices can reflect perfusion/functional defects, some other investigations have shown that cardiac function is preserved even in the presence of LVD. However, the presence of LVD suggests that the patient may probably progress to heart failure in the future,¹ which is explained by the uncoordinated contractions of the myocardial segments. The presence of LVD could predict cardiac death in patients with LV dysfunction and even those without LV dysfunction.¹⁷

Another advantage of LVD measurement by SPECT MPI is the simultaneous assessment of the perfusion, function, and dyssynchrony of the LV. The fact that LVD could be seen in asymptomatic patients may offer chances for intervention at an earlier stage of heart failure.^{1,18}

Accordingly, we hypothesized that mechanical dyssynchrony can cause LV regional wall motion polar map abnormalities in patients with a normal LV perfusion and a normal global LV function on MPI and a low pretest probability of ischemic heart disease (IHD). The present study was conducted with a view to increasing our insight into the role of mechanical dyssynchrony in abnormal LV wall motion polar maps among patients with a normal LV perfusion, a normal ECG, and a low probability of IHD.

METHODS

Study Design and Population

Totally, 181 patients who were at least 18 years of age and were clinically referred for SPECT MPI to the Nuclear Medicine Department of Rajaie Cardiovascular Medical and Research Center were included in the study. The patients had a low likelihood of IHD (<15%) as determined by the estimation of the pretest probability of coronary artery disease in terms of sex, age, and the symptoms and risk factors of coronary artery disease based on the guidelines of the American College of Cardiology/American Heart Association (ACC/AHA). The patients' myocardial perfusion and function based on gated MPI studies were normal, characterized as a summed stress score of less than 4, a lung-to-heart uptake ratio of less than 0.4, or a transient ischemic dilation for exercise stress score of less than 1.1 and a stress with dipyridamole score of less than 1.15. A normal myocardial function was defined as a global left ventricular ejection fraction

(LVEF) of greater than 50%, as well as a summed motion score and summed thickening score of 0.¹⁹ The exclusion criteria included dysrhythmias, subdiaphragm activities, patient motions, ECG abnormal conductions, and low counts. The patients excluded had a history of myocardial infarction, prior sternotomy, arterial fibrillation or multiple premature ventricular contractions, and valvular heart disease (proven by echocardiographic study before MPI). The interpretation of the motion polar maps showed abnormal wall motion in at least one of the LV walls for 81 patients, whereas the other 100 patients had normal wall motion polar maps. There were 117 (64.6%) male and 64 (35.4%) female patients at a mean (\pm SD) age of 50.39 (\pm 11.65) years. Table 1 compares the demographic characteristics of the 2 groups. The current investigation is a cross-sectional analytic study performed in the Nuclear Medicine Research Department of Rajaie Cardiovascular Medical and Research Center. The study population consisted of patients with a low pretest probability of IHD based on the Framingham score and no dyssynchrony on ECG (QRS = 100 ms) who were referred for SPECT MPI.

The study protocol was approved by the institutional ethics committee. The objectives of the study were explained to the patients, and written informed consent was obtained prior to participation. The study objectives and protocols were in conformity with the Declaration of Helsinki.

ECG-Gated SPECT MPI

The patients' demographic data were gathered; they included age, gender, height, and weight. Resting ECG and stress/rest SPECT MPI using 350–700 MBq technetium-99m (^{99m}Tc) sestamibi were performed for all the patients according to the standard protocol. For image acquisition, a dual-head gamma camera (Symbia T2,

Siemens Healthcare) equipped with CT-attenuation correction was used. Thirty-two images at 30-second projections were acquired 45 to 60 minutes following injection with a parallel-hole low-energy high-resolution collimator and 64 \times 64 matrix size. Normal perfusion was defined as a summed stress score of less than 4. The appropriateness (beat-to-beat variations and reject beats) of the images was evaluated by quantification using Quantitative Gated SPECT (QGS) software packages (version 0.4, May 2009). The images were interpreted by 2 qualified and experienced nuclear medicine specialists.

Phase analysis parameters, comprised of entropy, the phase standard deviation (PSD), and the phase histogram bandwidth (PHB), were recorded. In addition, LV function indices, consisting of LVEF, the end-diastolic volume (EDV), the end-systolic volume (ESV), the peak filling rate (PFR), and the time-to-peak filling (TTPF), were documented. According to the presence or absence of regional wall motion polar map abnormalities, the patients were categorized into 2 groups: Group A: 81 patients with abnormal regional wall motion, and Group B: 100 patients with normal wall motion polar maps.

Statistical Analysis

Descriptive indices, consisting of frequencies and percentages, were used to express the categorical data. The continuous variables were examined for normal distribution using the Kolmogorov–Smirnov test. The normally distributed variables (ie, age, LVEF, EDV, and the entropy of all the regional walls except the septal and apical walls) were summarized using the mean and the standard deviation, and the 2 groups were compared using the 2-sample *t*-test by considering a *P*-value of less than 0.05. For the data with non-normal distributions (the body mass index, ESV, PFR, TTPF, PSD,

PHB, and the septal and apical wall entropy), the Mann–Whitney U test was utilized between the experimental and control groups. The χ^2 test was applied to compare gender between the groups. All the analyses were performed with the SPSS software (SPSS Inc, Chicago, IL, USA).

RESULTS

The demographic characteristics of the 2 study groups are depicted in Table 1. As is demonstrated in Table 1, whereas the indices of perfusion, volume, and function (systolic and diastolic) were within the normal range in both groups, there were statistically significant differences with regard to LVEF (%), EDV (mL), ESV (mL), PFR (EDV/s), and TTPF (ms) between the 2 groups. Phase analysis indices indicated significantly higher entropy values in all the LV walls in the patients with post-stress abnormal wall motion polar maps (Group A) than in the patients without abnormal wall motion polar maps (Group B) ($P < 0.0001$) (Table 2).

Overall, PHB and PSD in 5 segments of the LV walls were significantly higher in Group A. In addition, although the PSD of the apical wall was relatively higher in Group A ($P = 0.036$), there was no statistically significant difference between the 2 groups apropos of the PHB of the apex ($P = 0.063$). Figures 1 to 4 show the findings in a 42-year-old patient with an abnormal wall motion polar map (Group A) in the phase analysis. Figure 1 and Figure 2, respectively, illustrate normal findings obtained from the rest and exercise ECG and from the 2-day ^{99m}Tc -MIBI protocol with exercise stress and gated SPECT-CT of the aforementioned patient, who had atypical chest pains and normal perfusion. Figure 3 and Figure 4, correspondingly, show that, despite a normal global EF and a normal diastolic function, the patient had abnormal wall motion polar map phase indices (entropy = 44%, PHB = 36.0°, and PSD = ± 10), particularly at the septal wall.

Table 1: Comparisons of the demographic variables between the 2 groups

		Abnormal Wall Motion Polar Maps: Group A (n = 81)	Normal Wall Motion Polar Maps: Group B (n = 100)	P-value
Gender	Male	61 (52.1%)	56 (47.9%)	0.007a
	Female	20 (31.2%)	44 (68.8%)	
Age ^b		53.15 (± 14.26)	48.47 (± 9.76)	0.013c
BMI ^d		26.45 (24.50–29.35)	28.40 (26.51–31.93)	<0.0001e
LVEF (%) ^b		65.13 (± 8.97)	77.08 (± 8.46)	<0.0001c
LV EDV (mL) ^b		75.06 (± 19.32)	59.78 (± 18.71)	<0.0001c
LV ESV (mL) ^d		27.00 (19.00–35.50)	13.50 (8.00–22.00)	<0.0001e
PFR (EDV/s) ^d		2.67 (2.00–3.26)	3.41 (2.83–4.01)	<0.0001e
TTPF (ms) ^d		148.00 (117.00–169.50)	161.00 (146.00–177.00)	0.002e

^a χ^2 test

^b Data are presented as the mean (the standard deviation).

^c Student t -test

^d Data are presented as the median (IQR)

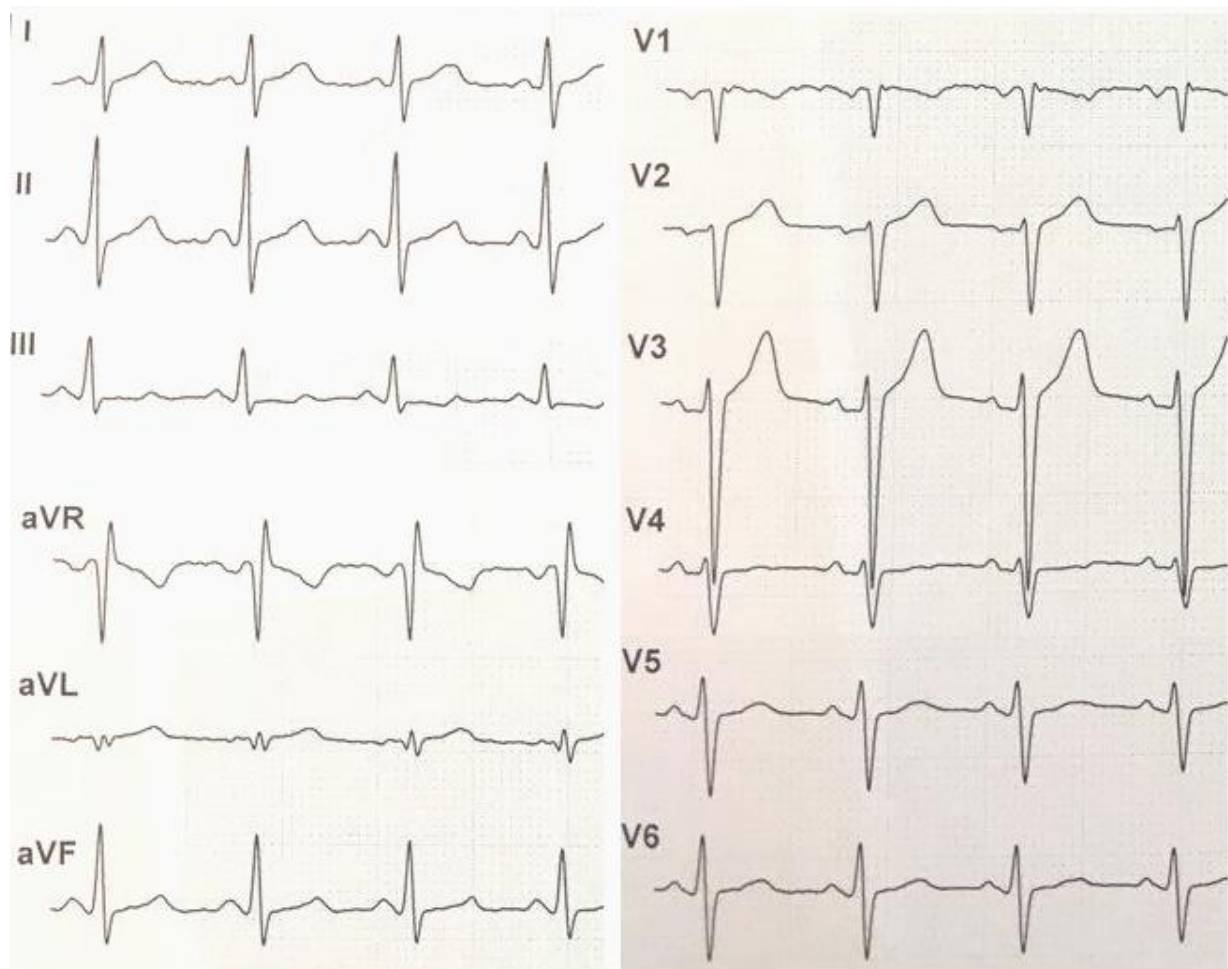
^e Mann–Whitney U test

BMI, Body mass index; LV, Left ventricular; EDV, End-diastolic volume; ESV, End-systolic volume; PFR, Peak filling rate; TTPF, Time-to-peak filling

Table 2: Comparisons of phase analysis indices between Group A (abnormal wall motion polar maps) and Group B (normal wall motion polar maps)

		Entropy	PHB	PSD
Anterior wall	Group A	33.58 (\pm 10.62)	30 (18–36)	7.40 (4.85–10.55)
	Group B	25.28 (\pm 8.79)	18 (18–24)	4.60 (3.32–5.87)
	P-value	<0.0001 ^a	< 0.0001 ^b	< 0.0001 ^b
Lateral wall	Group A	33.58 (\pm 10.62)	30 (18–42)	7.40 (4.65–11.80)
	Group B	25.28 (\pm 8.79)	18 (18–24)	4.75 (3.22–6.90)
	P-value	< 0.0001 ^a	< 0.0001 ^b	< 0.0001 ^b
Inferior wall	Group A	30.87 (\pm 10.05)	24 (18–36)	6.20 (4.25–9.90)
	Group B	24.10 (\pm 8.76)	18 (12–24)	4.15 (3.12–5.85)
	P-value	< 0.0001 ^a	< 0.0001 ^b	< 0.0001 ^b
Septal wall	Group A	33 (24–43)	30 (18–42)	6.70 (4.05–11.25)
	Group B	23 (17–27)	18 (12–18)	3.85 (2.90–4.87)
	P-value	< 0.0001 ^b	< 0.0001 ^b	< 0.0001 ^b
Apex	Group A	15 (7–19)	12 (12–18)	2.70 (1.65–3.25)
	Group B	12 (4–16)	12 (6–12)	2.35 (1.20–2.90)
	P-value	0.030 ^b	0.063 ^b	0.036 ^b

^a Student *t*-test, ^b Mann–Whitney *U* test, PHB and PSD in degrees and entropy in percentages
PHB, Phase histogram bandwidth; PSD, Phase standard deviation

**Figure 1:** Rest and exercise electrocardiogram of a 42-year-old patient with atypical chest pains shows normal findings.

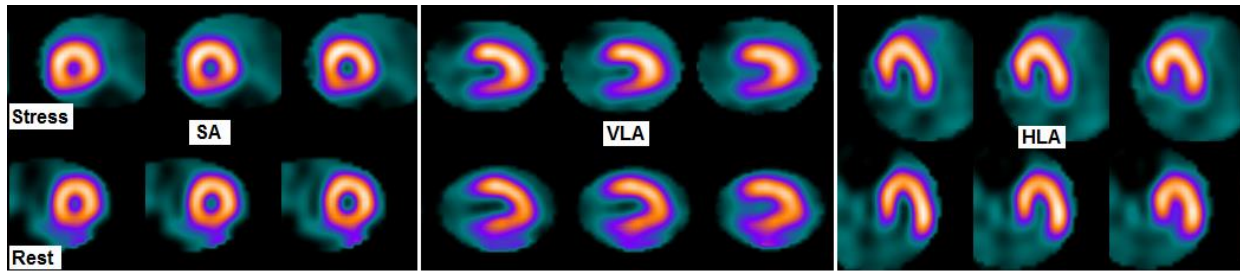


Figure 2: Two-day ^{99m}Tc -MIBI protocol with exercise stress and gated SPECT-CT images shows normal perfusion SA, Short axis; VLA, Vertical line axis; HLA, Horizontal long axis

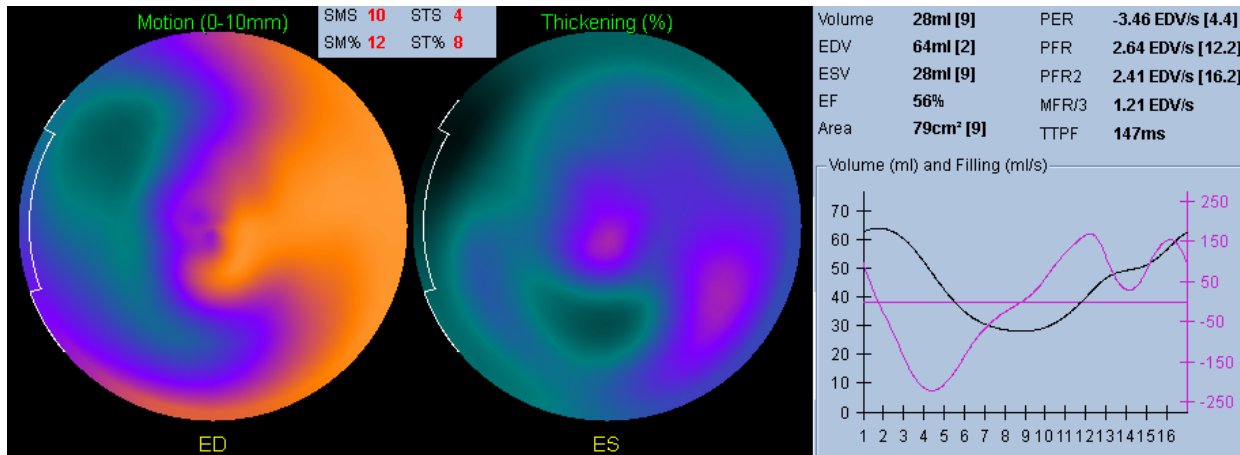


Figure 3: Abnormal septal wall motion polar map with a normal global ejection fraction and a normal diastolic function is illustrated herein.

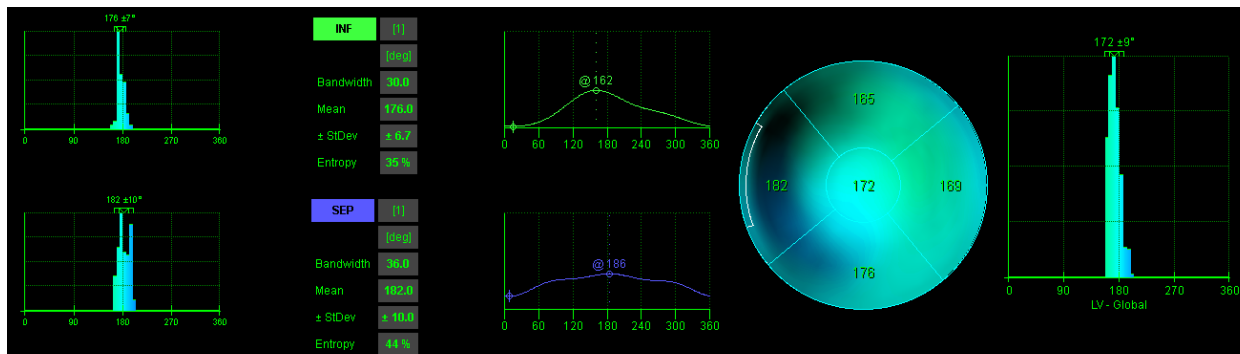


Figure 4: Abnormal phase indices, particularly at the septal wall, are depicted herein.

DISCUSSION

In the present study, we evaluated LV wall motion in 2 groups of patients: Group A had normal LV perfusion on MPI, a low pretest probability of IHD, and at the same time abnormal LV regional wall motion polar maps; whereas Group B had the same

conditions with just normal LV wall motion polar maps.

Gated MPI is applicable to the measurement of the function, perfusion, and dyssynchrony of the LV in a single study. In addition, the QGS software has proven to be a validated tool for the measurement of LVD parameters.²⁰ We, therefore, employed both in the

current study to evaluate LVD parameters and found statistically meaningful differences between Group A and Group B vis-à-vis regional dyssynchrony indices (ie, entropy, PHB, and PSD) in LV segments (ie, the apex and the anterior, lateral, inferior, and septal walls) (Table 2). Although the patients in both groups had a normal LV perfusion on MPI, a normal global LV function, and no evidence of IHD, our phase analysis by gated SPECT revealed significant differences regarding LVD between the groups. The entire study population had a normal ECG (Fig. 1), hence the low likelihood of the occurrence of electrical dyssynchrony in the face of a significant increase in mechanical synchrony indices.

We performed the present study based on the hypothesis that it would be possible to determine the cause of LV regional wall motion abnormalities (dyssynchrony) in patients who had a normal LV perfusion on MPI with a low probability of IHD. Our quantitative evaluation of phase analysis indices (ie, entropy, PHB, and PSD) in polar maps indicated considerable wall motion abnormalities. Abnormal wall motion polar maps in the presence of normal MPI are deemed a usual occurrence; consequently, a correct interpretation of such abnormalities requires an evaluation of the mechanical synchrony indices.

Recently, the phase analysis via gated SPECT to define LVD has gained attention. This method has been used in several patient populations to determine LVD, interventricular dyssynchrony,¹² and the effect of the His bundle pacing.²¹ Our findings showed that LV synchrony parameters (ie, entropy, PSD, and PHB) were higher in the group with abnormal wall motion polar maps. Thus, in order to accurately interpret gated MPI with abnormal wall motion polar maps, nuclear medicine and nuclear cardiology specialists need to pay special heed to LV synchrony

indices, aside from hypokinesia, akinesia, and dyskinesia.

Some studies have shown that LVD parameters are higher in both resting and stress phases in patients with ischemia.²² A previous study reported that LVD was seen only in patients with abnormal perfusion on MPI, but not among patients who had normal LV perfusion and function.¹¹ Nonetheless, our findings do not chime in with the mentioned results insofar as we observed changes in LVD parameters caused by abnormal wall motion polar maps (probably due to dyskinesia) even when stress MPI showed normal function and perfusion.

Strengths and Limitations

The cross-sectional design of the current study has its inherent limitations. We had no follow-up to determine the prognostic value of LVD in patients without evidence of IHD and with a normal LV function. Nevertheless, to the best of our knowledge, our study appears to be the first of its kind to assess LVD via the phase analysis in a sample of patients with a low probability of IHD.

CONCLUSIONS

In our study, LVD as evaluated by phase analysis indices (ie, entropy, PHB, and PSD) was a significant reason for abnormal LV regional wall motion polar maps in patients who had a normal LV perfusion, a low pretest probability of IHD, and a normal global EF. Generally, the wall motion polar map abnormalities observed in the study population according to phase analysis indices were probably due to dyssynchrony. Furthermore, the phase analysis indices for LV dyssynchrony could be used in patients with a low probability of IHD, a normal LV perfusion, and abnormal wall motion polar maps as a complementary tool for the interpreting physician.

New Knowledge Gained

Abnormal wall motion polar map assessments confer complementary information in MPI evaluations. The phase analysis helps nuclear medicine specialists to interpret wall motion polar map abnormalities carefully and accurately.

Acknowledgments

We would like to thank the staff of the Nuclear Medicine Department of Rajaie Cardiovascular Medical and Research Center for their collaboration in the imaging process.

Availability of Data and Materials

The data sets used in this study are available from the first author and corresponding author on reasonable request.

Disclosure

None of the authors of this paper has a financial or personal relationship with other people or organizations that could inappropriately influence or bias the content of the paper.

REFERENCES

1. Tavares A, Peclat T, Lima RSL. Prevalence and predictors of left intraventricular dyssynchrony determined by phase analysis in patients undergoing gated SPECT myocardial perfusion imaging. *The international journal of cardiovascular imaging* 2016; 32:845-52.
2. Yaghoobi N, Malek H. The age of reason for gated SPECT MPI to deal with cardiac dyssynchrony. *Research in cardiovascular medicine* 2015; 4.
3. Chen J, Garcia EV, Folks RD, Cooke CD, Faber TL, Tauxe EL et al. Onset of left ventricular mechanical contraction as determined by phase analysis of ECG-gated myocardial perfusion SPECT imaging: development of a diagnostic tool for assessment of cardiac mechanical
4. Malek H, Rayegan F, Firoozabadi H, Rastgou F, Haghjoo M, Bakhshandeh H et al. Determination of normal ranges of regional and global phase parameters using gated myocardial perfusion imaging with Cedars-Sinai's QGS software. *Iranian Journal of Nuclear Medicine* 2018; 26:16-21.
5. Lin X, Xu H, Zhao X, Folks RD, Garcia EV, Soman P et al. Repeatability of left ventricular dyssynchrony and function parameters in serial gated myocardial perfusion SPECT studies. *Journal of nuclear cardiology: official publication of the American Society of Nuclear Cardiology* 2010; 17:811-6.
6. AlJaroudi W, Koneru J, Heo J, Iskandrian AE. Impact of ischemia on left ventricular dyssynchrony by phase analysis of gated single photon emission computed tomography myocardial perfusion imaging. *Journal of Nuclear Cardiology* 2011; 18:36-42.
7. Atchley AE, Trimble MA, Samad Z, Shaw LK, Pagnanelli R, Chen J et al. Use of phase analysis of gated SPECT perfusion imaging to quantify dyssynchrony in patients with mild-to-moderate left ventricular dysfunction. *Journal of nuclear cardiology* 2009; 16:888.
8. Chen J, Garcia EV, Bax JJ, Iskandrian AE, Borges-Neto S, Soman P. SPECT myocardial perfusion imaging for the assessment of left ventricular mechanical dyssynchrony. *Journal of Nuclear Cardiology* 2011; 18:685-94.
9. Boogers MM, Van Kriekinge SD, Henneman MM, Ypenburg C, Van Bommel RJ, Boersma E et al. Quantitative gated SPECT-derived phase analysis on gated myocardial perfusion SPECT detects left ventricular dyssynchrony and predicts response to cardiac resynchronization therapy. *J Nucl Med* 2009; 50:718-25.
10. Chen J, Henneman MM, Trimble MA, Bax JJ, Borges-Neto S, Iskandrian AE et al. Assessment of left ventricular mechanical dyssynchrony by phase analysis of ECG-gated SPECT myocardial perfusion imaging. *Journal of nuclear cardiology* 2005; 12:687-95.

- Journal of Nuclear Cardiology 2008; 15:127-36.
11. Singh H, Patel CD, Sharma P, Naik N, Singh S, Narang R. Does perfusion pattern influence stress-induced changes in left ventricular mechanical dyssynchrony on thallium-201-gated SPECT myocardial perfusion imaging? Journal of Nuclear Cardiology 2015; 22:36-43.
 12. Zhou W, Jiang Z, Chen J, Garcia EV, Li D. Development and validation of a phase analysis tool to measure interventricular mechanical dyssynchrony from gated SPECT MPI. Journal of Nuclear Cardiology 2017; 24:1680-6.
 13. Malek H, Yaghoobi N, Hedayati R. Artifacts in Quantitative analysis of myocardial perfusion SPECT, using Cedars-Sinai QPS Software. Journal of Nuclear Cardiology 2017; 24:534-42.
 14. Rastgou F, Shojaeifard M, Amin A, Ghaedian T, Firoozabadi H, Malek H et al. Assessment of left ventricular mechanical dyssynchrony by phase analysis of gated-SPECT myocardial perfusion imaging and tissue Doppler imaging: Comparison between QGS and ECTb software packages. Journal of Nuclear Cardiology 2014; 21:1062-71.
 15. Shojaeifard M, Ghaedian T, Yaghoobi N, Malek H, Firoozabadi H, Bitarafan-Rajabi A et al. Comparison of gated SPECT myocardial perfusion imaging with echocardiography for the measurement of left ventricular volumes and ejection fraction in patients with severe heart failure. Research in cardiovascular medicine 2016; 5.
 16. van der Veen BJ, Al Younis I, Ajmone-Marsan N, Westenberg JJM, Bax JJ, Stokkel MPM et al. Ventricular dyssynchrony assessed by gated myocardial perfusion SPECT using a geometrical approach: a feasibility study. European Journal of Nuclear Medicine and Molecular Imaging 2012; 39:421-9.
 17. Zafir N, Nevzorov R, Bental T, Strasberg B, Gutstein A, Mats I et al. Prognostic value of left ventricular dyssynchrony by myocardial perfusion-gated SPECT in patients with normal and abnormal left ventricular functions. Journal of Nuclear Cardiology 2014; 21:532-40.
 18. Bitarafan-Rajabi A, Rajabi H, Rastgou F, Firoozabadi H, Yaghoobi N, Malek H et al. Influence of respiratory motion correction on quantification of myocardial perfusion SPECT. Journal of Nuclear Cardiology 2015; 22:1019-30.
 19. van Werkhoven JM, Schuijf JD, Gaemperli O, Jukema JW, Boersma E, Wijns W et al. Prognostic value of multislice computed tomography and gated single-photon emission computed tomography in patients with suspected coronary artery disease. J Am Coll Cardiol 2009; 53:623-32.
 20. Hess PL, Shaw LK, Fudim M, Iskandrian AE, Borges-Neto S. The prognostic value of mechanical left ventricular dyssynchrony defined by phase analysis from gated single-photon emission computed tomography myocardial perfusion imaging among patients with coronary heart disease. Journal of Nuclear Cardiology 2017; 24:482-90.
 21. Zhang J, Guo J, Hou X, Wang Y, Qian Z, Li K et al. Comparison of the effects of selective and non-selective His bundle pacing on cardiac electrical and mechanical synchrony. EP Europace 2017.
 22. Chen CC, Shen TY, Chang MC, Hung GU, Chen WC, Kao CH et al. Stress-induced myocardial ischemia is associated with early post-stress left ventricular mechanical dyssynchrony as assessed by phase analysis of 201Tl gated SPECT myocardial perfusion imaging. European journal of nuclear medicine and molecular imaging 2012; 39:1904-9.