

## Case Report

# *Percutaneous Coronary Intervention and Pulmonary Balloon Valvuloplasty in a 56-Year-Old Woman With Severe Valvular Pulmonary Stenosis: A Case Report*

Ata Firouzi<sup>1</sup>, MD; Omid Shafe\*<sup>1</sup>, MD;  
Farzad Kamali<sup>2</sup>, MD; Foroozan Asgari<sup>2</sup>, MS

## ABSTRACT

Percutaneous balloon pulmonary balloon valvuloplasty is the treatment of choice among patients with severe pulmonary stenosis. We describe a 56-year-old woman with severe pulmonary stenosis who presented with hemodynamic disturbances due to pulmonary thromboembolism during hospitalization.

Percutaneous pulmonary balloon valvuloplasty is a safe and effective treatment for valvular pulmonary stenosis. (*Iranian Heart Journal 2017; 18(1):51-55*)

**Keywords:** Severe valvular pulmonary stenosis, Percutaneous coronary intervention, Pulmonary balloon valvuloplasty

<sup>1</sup> Cardiovascular Intervention research Center, Rajaie Cardiovascular, Medical, and Research Center, Iran University of Medical Sciences, Tehran, I.R. Iran.

<sup>2</sup> Rajaie Cardiovascular, Medical, and Research Center, Iran University of Medical Sciences, Tehran, I.R. Iran.

**\*Corresponding Author:** Omid Shafe, MD; Rajaie Cardiovascular, Medical, and Research Center, Iran University of Medical Sciences, Tehran, I.R. Iran.

**E-mail:** omid-shafe@hotmail.com

**Tel:** 02123922088

**Received:** May 30, 2016

**Accepted:** August 25, 2016

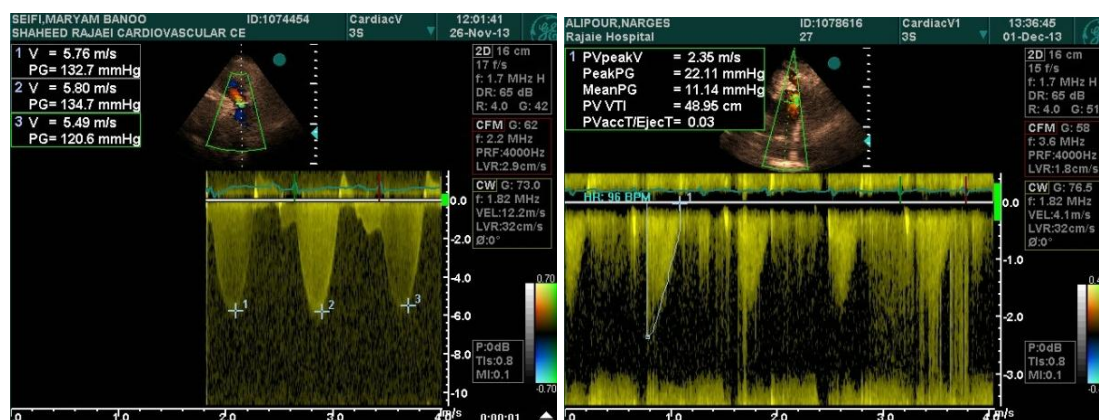
**B**alloon valvuloplasty for isolated valvular pulmonary stenosis (PS) provides nearly equivalent long-term gradient relief with less valvular insufficiency and less late ventricular ectopic activity than surgery.<sup>1, 2, 3</sup> This report illustrates percutaneous coronary intervention on a totally occluded left anterior descending coronary artery (LAD) and simultaneous percutaneous pulmonary balloon valvuloplasty in a 56-year-old woman.

## CASE REPORT

A 56-year-old hypertensive woman with valvular PS presented with progressive dyspnea (functional class II–III) and typical

chest pain of 2 months' duration. She was referred to our center for further diagnostic and therapeutic investigation. On physical examination, her vital signs were normal. The jugular venous pressure was raised, and there was a prominent left sternal border lift. Auscultation revealed a wide S2 splitting as well as a mid-systolic murmur with moderate intensity (ie, 3/6).

On echocardiography, there were biventricular failure (left ventricular ejection fraction = 25%), severe right ventricular enlargement, severe tricuspid regurgitation with a trans-regurgitation gradient of 115 mm Hg, and a severe valvular PS (peak pressure gradient = 120 mm Hg). The pulmonary valve annulus was measured at 22 mm (Fig. 1).



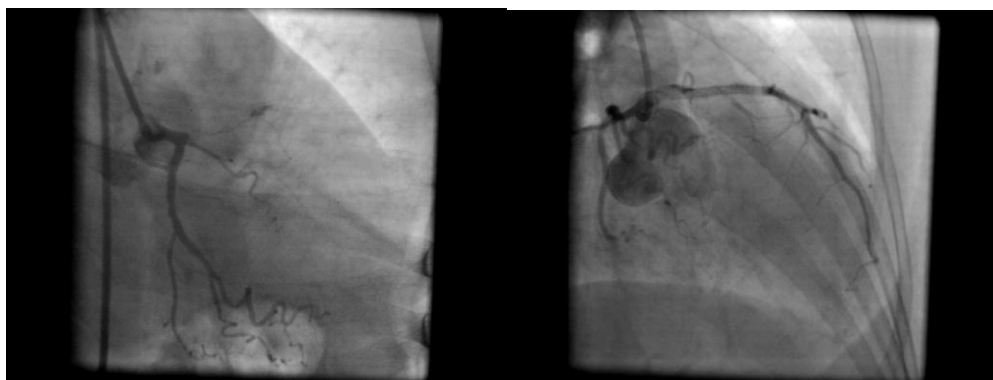
**Figure 1.** (Left) Transthoracic echocardiography (TTE) in the continuous wave Doppler mode shows a severe valvular pulmonary stenosis with a 130-mm Hg transvalvular gradient before balloon valvuloplasty. (Right) TTE in the continuous wave Doppler mode shows a nonsignificant residual pulmonary stenosis with a peak pressure gradient of about 20 mm Hg after balloon valvuloplasty.

Coronary angiography showed the occlusion of the LAD from the ostium with a good distal runoff.

During hospitalization, the patient became thermodynamically unstable. She became hypotensive and unconscious. Pulmonary computed tomography angiography was

performed and it showed segmental pulmonary thromboembolism PTE.

The estimated risk of surgery was high; therefore, we opted for medical treatment. After a 4-day supportive therapy, her hemodynamic instability improved and we decided to perform percutaneous coronary intervention and valvuloplasty (Fig. 2).



**Figure 2.** (Left) Selective coronary angiography in the right anterior oblique (RAO) caudal view shows a totally occluded left anterior descending coronary artery (LAD) from the ostial part with a faint antegrade runoff. (Right) Selective coronary angiography in the RAO view after successful percutaneous coronary intervention on the LAD.

## PROCEDURE AND RESULT

The wiring of the stenotic pulmonary valve proved extremely challenging as it was heavily calcified and severely stenotic (Fig. 4). Multiple attempts were made to cross the

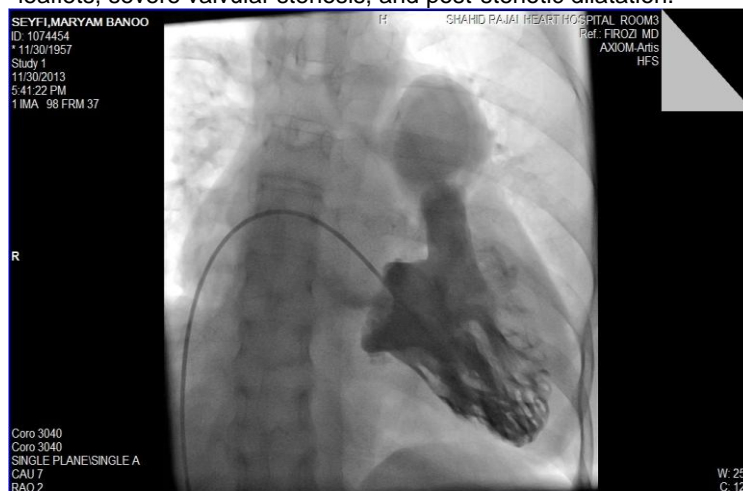wire, and finally a 0.035-inch straight wire was passed through the stenotic valve. As the wire passed through the stenosis, we found slight systemic hypotension, which was a sign for a high-risk situation and a very severe stenosis. Passing a multipurpose A1 catheter

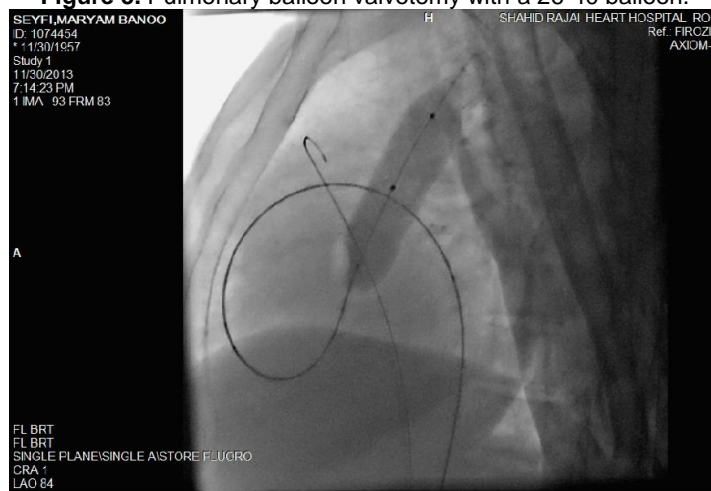
(6F size) caused more systemic hypotension (135/80 to 95/60 mm Hg). A severe peak-to-peak pressure gradient of about 100 mm Hg was measured between the right ventricle and the right atrium. After exchanging the non-stiff 0.035 wire with a stiff one, we utilized 2 different balloons for valvuloplasty to reduce the risk of procedural complications. The 1st balloon was an 8–40 Nucleus balloon used for predilation, followed by a 26–40 balloon to wrap up valvuloplasty. We inflated the 1st balloon twice, and there was a waist showing significant stenosis. The 2nd balloon was inflated 3 times, and the waist was eliminated after inflation (Fig. 5). Deep hypotension occurred during inflation; we, therefore, minimized the whole time of the crossing, inflating, and deflating of the balloons to less than 8 seconds. After valvuloplasty, we found that there was a 25 mm Hg peak-to-peak pressure gradient between the right ventricle and the pulmonary artery, which was the effect of infundibular stenosis due to severe right ventricular hypertrophy. Our final right ventricular injection proved the infundibular hypertrophy, so we considered a saline bolus

injection so as to reduce this effect. Much as we expected hypotension due to the infundibular hypertrophy, it did not occur during the course of hospitalization after the procedure. Postprocedural echocardiography showed a left ventricular ejection fraction of about 30%, thickened and dome-shaped pulmonary valve leaflets with moderate pulmonary insufficiency, and no significant transvalvular stenosis with a peak pressure gradient of 20 mm Hg (Fig. 2).

Finally, the patient was discharged in good condition with antiplatelet and heart failure medications. Two months after balloon valvuloplasty and percutaneous coronary intervention, her symptoms were significantly relieved and follow-up transthoracic echocardiography showed a left ventricular ejection fraction of 35%, moderate right ventricular enlargement with mild-to-moderate right ventricular systolic dysfunction, trivial tricuspid regurgitation, and moderate pulmonary insufficiency with no significant residual PS (pulmonary pressure gradient = 12 mm Hg).

**Figure 4.** Right ventricular injection with a pigtail catheter shows severe right ventricular enlargement, thickened pulmonary valve leaflets, severe valvular stenosis, and post-stenotic dilatation.



**Figure 5.** Pulmonary balloon valvotomy with a 26-40 balloon.

## DISCUSSION

PS is a relatively common congenital defect that occurs in approximately 10% of children with congenital heart diseases. It is usually associated with a benign clinical course, and there is, therefore, a high rate of survival to adulthood. The common cause of valvular PS is congenital, and acquired causes are rare.<sup>4,5</sup> Patients with congenital valvular PS undergoing balloon valvuloplasty have a low rate of restenosis.<sup>6</sup>

Balloon valvuloplasty is recommended in asymptomatic patients with a dome-shaped pulmonary valve and a peak instantaneous Doppler pressure gradient  $> 60$  mm Hg or a mean pressure Doppler gradient  $> 40$  mm Hg. This modality is also recommended in symptomatic patients with a dome-shaped pulmonary valve and a peak instantaneous Doppler pressure gradient  $> 50$  mm Hg or a mean pressure Doppler gradient  $> 30$  mm Hg. Balloon valvuloplasty is not recommended for asymptomatic patients with a peak instantaneous gradient by Doppler  $< 50$  mm Hg in the presence of normal cardiac output, for symptomatic patients with PS and severe pulmonary regurgitation, and for symptomatic patients with a peak instantaneous pressure gradient by Doppler  $< 30$  mm Hg.<sup>7</sup> According to the indications noted above, our patient could be treated surgically or via an

interventional approach. The EuroSCORE for this patient was estimated to be 7, which means a high risk of surgery. Accordingly, our cardiac surgeons decided not to go on with the surgical approach.

Given the severity of the PS, crossing the lesion was very challenging. Finally, we managed to cross a straight-tipped wire through the pulmonary valve, which resulted in a drop in blood pressure. This was another sign for the severity of the PS in the patient. This phenomenon is known in severely stenosed aortic valve as “the Brockenbrough-Braunwald-Morrow sign”. We minimized the balloon inflation time to avoid cardiovascular collapse. Also, according to the recommendations, the size of balloons used for valvuloplasty in PS should be chosen at least 120% larger than the pulmonary valve annulus diameter.<sup>8</sup> Consequently, we used a 26-40 balloon for valvuloplasty (pulmonary valve annulus diameter was 22 mm), after predilation with a smaller size balloon (8-40) to reduce the probability of valve rupture and minimize the time of balloon inflation. As was mentioned before, because of the very severe stenotic pulmonary valve and difficulty in crossing the wire, the evaluation of the pressure gradient between the pulmonary artery and the right ventricle could not be performed simultaneously because one should pull back an end-hole catheter through a

stenotic valve to detect the pressure gradient. After the dilation of the pulmonary valve, we encountered a residual pressure gradient due to right ventricular outflow tract hypertrophy, which had been diagnosed before the procedure via echocardiographic evaluation, and a drop in blood pressure as its consequence. There was about a 30 mm Hg residual pressure gradient after balloon dilation, but no drop in blood pressure was detected, although we administered a saline injection and beta-blockers to prevent this situation. Nonetheless, there is an unresolved question as to the diagnosis of pulmonary thromboembolism in this patient inasmuch as she had severe PS and small amounts of clot, which can cause complete obstruction in the right ventricular outflow tract and cardiovascular collapse. Whether or not this thrombosis was *in situ* or was embolized has remained unclear and needs further observations.

## REFERENCES

1. Lin SC, Huang JJ, Hsu KI, Balloon valvuloplasty in adult with congenital valvular pulmonary stenosis. *Acta cardiologica Sinica* 2004;20:147-53
2. O' Connor BK, Beekman RH. Intermediate term Outcome after balloon valvuloplasty: comparison with a matched surgical control group. *JACC*. July 1992;20:169-73
3. Miller GAH Balloon valvuloplasty and angioplasty in congenital heart disease. *Br Heart J* 1985; 54:285-9
4. Compball M. Factors in the etiology of pulmonary stenosis. *Br Heart J*. 1962 September; 24(5): 625-632.
5. Snellen HA, Hartman H Buis-Liem TN, et al. Pulmonic stenosis. *Circulation* 1968;38:93-101.
6. P S Rao, O Galal. M Patnana. Result of 3 to 10 year follow up of balloon dilatation of pulmonary valve. *Haert* 1998; 80:591-595
7. Warnes CA, Williams RG, Bashore TM, et al. ACC/AHA 2008 Guidelines for the Management of Adults with Congenital Heart Disease: a report of the American College of Cardiology/American Heart Association Task Force on Practice Guidelines (writing committee to develop guidelines on the management of adults with congenital heart disease). *Circulation* 2008; 118:e714.
8. Mc Crindle BW, Kan JS. Kan. Long term results after pulmonary valvuloplasty. *Circulation* 1991; 83:1915-22.