

## Case Report

### *Brucellosis Aortic Valve Endocarditis with Paravalvular Abscess: Case Report*

Hamid Hoseinikhah, MD<sup>1\*</sup>; Aliasghar Moeinipour, MD<sup>1</sup>;  
Mehrdad Esmailzadeh, MD<sup>1</sup>; Hossein Safari, MD<sup>1</sup>

#### Abstract

Brucellosis is an infectious disease that can involve the cardiovascular system. Brucella aortic valve endocarditis is an uncommon presentation of it with aortic valve regurgitation and heart failure. Diagnosis of brucella endocarditis of aortic valve is done in most cases with echocardiography. Successful management of this disease requires a combination of appropriate antibiotic treatment and surgical valve replacement, followed by a long duration of antibiotic therapy postoperatively (Doxycycline and Rifampicin).

We describe a 36-year-old man, with brucella endocarditis of aortic valve and paravalvular abscess, who was managed via aortic valve replacement using a mechanical prosthesis with good results. (*Iranian Heart Journal 2015; 16(1): 38-41*)

**Keywords:** ■Brucellosis; ■Endocarditis; ■Paravalvular abscess

<sup>1</sup> Department of Cardiac Surgery, Imam Reza Hospital, Mashhad University of Medical Sciences, Mashhad, IRAN.

\*Corresponding Author: Hamid Hoseinikhah, MD  
Tel: 09153046163 E-mail: hoseinikhahh@mums.ac.ir

Received: February 1, 2015

Accepted: April 2, 2015

Brucellosis is a common and endemic disease in Iran. Many cases of infectious brucellosis are likely to go undiagnosed.<sup>1</sup> Infectious brucellosis has a large number of systemic presentations and can affect any organ, especially the musculoskeletal and gastrointestinal systems. Cardiovascular involvement in the course of infectious brucellosis is uncommon, but the most common cardiac disease caused by infectious

brucellosis is cardiac valve involvement and, in particular, aortic valve endocarditis.<sup>8</sup> Endocarditis of the aortic valve can lead to significant morbidity and also mortality rates in the wake of the extensive destruction of the aortic leaflet, which can be complicated by leaflet perforation and vegetation formation and leaflet coaptation failure. All of these conditions can ultimately give rise to severe aortic valve insufficiency.<sup>5</sup> The presence of a

large and mobile vegetation on the aortic valve leaflet can lead to distal systemic embolization and central nervous system sequelae with major morbidity.

One of the other rare presentations of brucella endocarditis of aortic valve is paravalvular abscess formation, which may become fistulized or perforated as was the case in our patient.

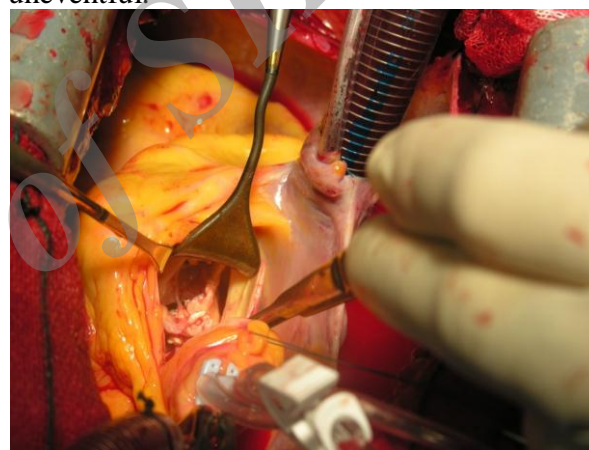
### Case Presentation

We describe a 36-year-old man with a documented history of infectious brucellosis of 5 years' duration, who received appropriate treatment (Doxycycline and Rifampicin antibiotic regime). The patient referred to us with symptoms of dyspnea of a few months' duration. In clinical evaluation, he had holodiastolic murmur in the aortic position. Laboratory data showed mild leukocytosis, elevated ESR and CRP, and positive Wright test. Transthoracic echocardiography demonstrated a destroyed aortic valve with severe aortic valve regurgitation and multiple vegetations on the aortic leaflet, the largest of which was about 0.8 cm in the right coronary cusp of the aortic valve.

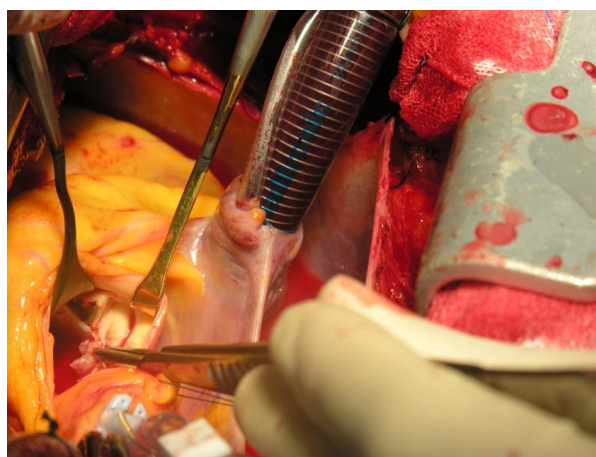
The specific presentation in this case was a 0.5×0.5cm cavity in the area between the right coronary cusp and the non-coronary cusp, which mimicked a paravalvular abscess. In echocardiographic evaluation, the patient had mild dilation of the left ventricular cavity but with an acceptable ejection fraction (EF=50%).

After a complete preoperative evaluation of the patient, he was scheduled for surgery. After median sternotomy incision and opening the pericardium, Heparin was administrated (3 mg/kg), and the aortic and right atrium purse string suture was applied. Arterial and venous cannulation was accomplished. After appropriate ACT, cardiopulmonary bypass was initiated and aortic cross-clamping was done. Moderate hypothermia was achieved with an antegrade and direct cardioplegia infusion. Thereafter, oblique aortotomy was performed.

Evaluation of the aortic valve revealed the malcoaptation and thinness of the aortic leaflet. Moreover, there were multiple vegetations on the aortic leaflet in addition to a paravalvular abscess in the right and non-coronary cusps of the aortic valve (Figures 1 and 2). First, a complete excision of the aortic leaflet, followed by aggressive irrigation, was done. After sizing of the aortic annulus, a mechanical prosthetic aortic valve was reimplanted (ST. Jude #23). Then, the cavity of the paravalvular abscess was deleted along the suture line of the prosthetic valve. The patient was weaned from cardiopulmonary bypass easily, and his recovery was uneventful.



**Figure 1.** Vegetations on the aortic leaflet with a paravalvular abscess



**Figure 2.** Paravalvular abscess after the excision of aortic valve

Postoperative transthoracic echocardiographic examination of the patient was done on the 3<sup>rd</sup>

and 7<sup>th</sup> postoperative days and showed the good hemodynamics of the prosthetic aortic valve and no paravalvular leakage or any sign of recurrent infection. Appropriate antibiotic treatment, consisting of Doxycycline and Rifampicin, was continued postoperatively for 2 months. The patient was discharged on the 10<sup>th</sup> postoperative day in good clinical condition. Follow-up at the 1<sup>st</sup> and 4<sup>th</sup> weeks after surgery showed excellent results. In the latest echocardiographic examination of the patient, carried out 6 months after surgery, the prosthetic aortic valve was detected with good hemodynamics and without any signs of recurrent endocarditis.

### Discussion

Brucellosis is a common health problem in Iran and Middle Eastern countries.<sup>1,7</sup> A large number of patients with this disease usually remain undiagnosed. The common way of contamination is ingestion of infected and contaminated animal products, especially milk products. Brucellosis is a systemic disease that can affect any organ, but the musculoskeletal system accounts for the most common involvement.<sup>3</sup> Although the cardiovascular presentation of infectious brucellosis is not very common, it can manifest itself as endocarditis, pericarditis, and pericardial effusion.<sup>4,6</sup> The aortic valve is predominately the valve that is affected in the course of brucellosis endocarditis (about 45%-75% of infected valves). Brucella endocarditis of aortic valve can cause great morbidity and mortality. The presentation of patients with brucella endocarditis of aortic valve is the systemic manifestation of brucellosis with fever, malaise, weight loss, myalgia, and symptoms and signs of aortic valve regurgitation and cardiac failure. Most patients complain of dyspnea and chest pain. The diagnosis of aortic valve endocarditis is confirmed with transthoracic and transesophageal echocardiography in most cases. The majority of the cases of brucella

endocarditis of aortic valve require surgical intervention due to heart failure and aortic regurgitation and also infected aortic valve resistant to antibiotic therapy or large and mobile vegetations on the aortic leaflet with the possibility of distal embolization. The first surgical operation for brucella endocarditis of aortic valve was done in 1967 by Ehrenhaf, who replaced the aortic valve, but his patient died from the reinfection of the valve.<sup>10</sup> Aortic valve replacement is deemed the gold-standard procedure by cardiac surgeons. Prosthetic valves that can be applied are mechanical or biological prostheses, both of which can be used successfully.

Postoperatively, patients with brucella endocarditis of aortic valve need long durations of antibiotic therapy, which can vary from 2 weeks to 6 months and can be given intravenously or orally.<sup>11</sup> Complete eradication of brucellosis is necessary to avoid the recurrence of infection in the prosthetic aortic valve and requires appropriate antibiotics and also close follow-up of the patients with serology testing for the early detection of persistent and recurrent infection and periodic echocardiographic examinations for the diagnosis of the signs of endocarditis in the prosthetic valve. Finally, for excellent results in the treatment of brucella endocarditis of aortic valve, a combination of appropriate antibiotic therapy and surgery is recommended.<sup>9</sup> Be that as it may, some authors believe that in some selected cases with brucella aortic valve endocarditis that have no signs of valve destruction and valve regurgitation, antibiotic therapy only can be applied but with close follow-up.<sup>9</sup>

### References

1. Kilic S, Dizbay M, Cabadak H. In vitro activity of tigecycline, tetracycline and fluroquinolone against *Brucella melitensis*. J Chemother 2008;20:33-7.
2. Aliashghar Moinipour, Mohammad Abbasi, Hamid Hoseinikhah, Nahid Zirak. Aortic Valve

- Endocarditis: A rare presentation of Brucellosis. The Iranian Journal of Cradiac surgery MAY 2012,3(4):38-40
3. Colmenero JD, Reguera JM, Martos F. Complications associated with BrucellaMelitenis infection: a study of 530 cases. Medicine ( Baltimore) 1996;75:195-211.
  4. Salata RA, Ravdin JT. Mandel GL, Douglas RD,Bennet JE. Principles and practice of infectious disease. New York: Jhon Wiley , 1985:1283-90.
  5. Buchanan TM, Faber IC, Feldman RA. Brucellosis in United stetes1960-1972. An abattoir- associated disease. Clinical feature and therapy. Medicine (Baltimore) 1974;53: 403-13.
  6. Peery TM, Belter LF, Brucellosis and Heart disease : a Review of Literature and report of new cases . Am J pathol 1960;36:673-97.
  7. Mert A, Ozaras R, Tabak F. the sensitivity and specificity of Brucellaagglutination tests. diagnMicribiol infect dis 2003;46:241-3.
  8. SerkanCay, GokselCagirci, OrhanMaden, YucelBalbay, SinanAydogdu. Brucella endocarditis- a registry study. Kardiologi-apolska 2009;67:3
  9. Hudson RA. Brucellaabortousendocarditis: a case. Circulation 1957;16:411-13
  10. Ehrenhaft JL. In discussion of a paper by Kaiser GC, Wilman VL, Thurmann M, Hanlon CR. Valve replacement in cases of aortic insufficiency due to active endocarditis. J ThoracSurg 1967;54:491.
  11. Ozsoyler L, Yilik L, Bozok S. Brucella Endocarditis: the important of surgical timing after medical treatment . ProgCardiovasc Dis 2005;47:226-9.

Archive of SID