

# Deep Hypothermic Circulatory Arrest (DHCA) in a Man Undergoing Aortic Aneurysm Dissection Surgery

Masoud Tarbiat MD<sup>1</sup>, Abbas Sedighinejad MD<sup>2\*</sup>, Babak Manafi MD<sup>3</sup>, Afshin Farhanchi MD<sup>4</sup>, Vali Imantalab MD<sup>2</sup>, Ali Mirmansouri MD<sup>2</sup>

## Abstract

A 55-year-old man with aortic aneurysm dissection was candidate for surgery. His blood pressure was low and he had chest pain. After sternotomy and extraction of clots, cardiac collapse occurred and deep hypothermic circulatory arrest (DHCA) was started with all of the methods for brain protection. After the operation, the patient was completely alert and conscious without any problems. (*Iranian Heart Journal 2012; 13(3):46-53*).

**Keywords:** Aortic Surgery ■ Deep Hypothermia ■ Neurologic Deficits

## Introduction

The use of deep hypothermic circulatory arrest (DHCA) is a method of cerebral protection during aortic surgery. First described in 1975 (1), DHCA is used based on two basic concepts: 1) disruption of the cerebral circulation with the full recovery of the neurologic function and 2) decrease in the brain metabolic rate with the manipulation of temperature (2). This technique allows the surgeon to work in a bloodless field uncluttered by proximal clamps and perfusion cannulae. Its relative safety may be enhanced by the use of various adjuncts such as surface cooling of the head with ice packs, retrograde cerebral perfusion (RCP), and selective antegrade cerebral perfusion (SACP) (3), particularly if DHCA is prolonged.

## Case Report

A 55-year-old man was admitted to our hospital for repair of an aortic aneurysmal

dissection. The patient had experienced chest pain radiating to the back, dyspnea, and low blood pressure (unstable hemodynamic). He had a history of hypertension. Preoperatively, chest radiography revealed widening of the mediastinum (Figure 1), and transesophageal echocardiography (TEE) revealed an intimal flap from the sinotubular junction of the ascending aorta to the end aorta arch. The descending aorta was intact, and the ejection fraction was 50%.

The patient was transported to the operating room in a lethargic state and prepared for the induction of anesthesia. In the operating room, the patient was monitored via standard ECG (II and V5), pulse oximeter, and the BIS (Bispectral index) (Spacelabs Medical Model No 90491). Thereafter, the veins on both arms were cannulated by 16-G catheters under local anesthesia with Lidocaine 1%.

Received December 2012; Accepted for publication December 2012

1. Assistant professor of cardiac anesthesia, Hamedan University of Medical Sciences, Akbatan Heart Hospital, Hamedan, Iran

2. Assistant professor of cardiac anesthesia, Guilan University of Medical Sciences, Heshmat Heart Hospital, Rasht, Iran

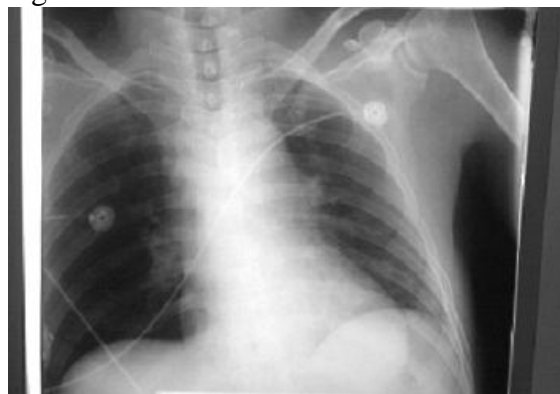3. Cardiac surgeon, Assistant professor of cardiac surgery, Hamedan University of Medical Sciences, Akbatan Heart Hospital

4. Assistant professor of anesthesiology, Hamedan University of Medical Sciences, Akbatan Heart Hospital

\* Corresponding Author: Dr. Sedighinejad Abbas. Anesthesiology Research Center, Guilan University of Medical Sciences

Tel: 0098-9111325712, Email :A\_sedighinejad@yahoo.com

Figure 1.



The catheters were inserted in the left radial and left femoral arteries to monitor blood pressure (20-G catheter Arrow REF SAC 00820). Pre oxygenation by 100% oxygen about 3 minutes before induction was done. The patient was induced with 50 $\mu$ g Sufentanil, 16mg Etomidate, and 90mg Succinylcholine. After intubation and fixation of the endotracheal tube, 20 mg Cisatracurium was injected. Anesthesia was maintained by Propofol infusion 50-75 mg/kg/min, Sufentanil 2 $\mu$ g/kg/h, Cisatracurium 2 $\mu$ g/kg/min, and Dexamethasone 16mg. Additionally, vitamin C 500mg (infusion) was administered. A tri-lumen catheter was then inserted in the right subclavian vein (Arrow-Howestm multi-lumen central venous catheterization set with Blue Flex Tip<sup>®</sup> catheter No.7 Fr.). The right femoral artery was prepared for arterial cannula insertion, and a nasopharyngeal temperature probe was inserted.

After sternotomy and extraction of the extensive clots, cardiac collapse occurred due to the tearing of the aorta. Suddenly the blood pressure decreased, necessitating resuscitation. Adrenalin 0.25mg was injected, and internal cardiac massage was done. After a few minutes, the patient was stabilized and the surgeon continued his work by inserting a bicaval cannula. Heparin 3mg/kg was administered, and ACT was monitored until it reached 735 seconds. Preparation for DHCA was instituted about 45 minutes after cannula insertion, and the following drugs were given intravenously:

Thiopental sodium 250 mg; Midazolam 5 mg; Magnesium sulfate 2 gr; Methylprednisolone 500 g; and Lidocaine 85 mg. Moreover, heparin 1.5 mg/kg was added to the first dose, and Mannitol 12.5 gr was also added to the prime solution.

The patient's head was packed in ice (made from crushed ice placed in plastic bags). Five minutes were allowed to elapse to circulate the medications to ensure perfusion of the vessel-rich organs such as brain, liver, and kidneys. Extracorporeal circulation was performed with a standard membrane oxygenator (Medtronic TRILLIUM<sup>®</sup>, AFFINITY<sup>®</sup> NT). The pump flow rate was maintained between 1.5 and 2 L/m<sup>2</sup>. Cardioplegic solutions were infused to arrest the heart. As soon as asystole was established, the pump was turned off. The BIS decreased from 50 to zero after that.

The surgeon repaired the aorta arch at DHCA and used antegrade cerebral perfusion (ACP) in the left common carotid and retrograde cerebral perfusion (RCP) in the superior vena cava for 5 minutes at the end of aorta arch repair for deairing. The total time of non-perfusion or DHCA was 55 minutes at a core body temperature of 18°C (monitored via a nasopharyngeal temperature probe). When the pump was turned on for normal bypass, sodium bicarbonate 100 Meq (1.5 Meq/kg) was administered. The patient was slowly warmed to 36°C. Modified Ultrafiltration (MUF) was also performed at this time and the ice packs were removed. The BIS increased from zero to 50 and was kept in 50 to 60 during the operation. After the commencement of CBP, the anesthetic state was continued with Propofol, Cisatracurium, and Sufentanil infusion.

The operation was uneventful and the patient was transferred to the open heart intensive care unit (ICU), where the patient was extubated after 8 hours. He was completely alert with no hemodynamic complications, but he had paresthesia in right extremities. His motor dysfunction was 3/5 muscular force and he

was examined by a neurologist. After 24 hours in the ICU, the patient regained full muscular force without any neurological sequelae. At six months' follow-up, there was no evidence of renal, cerebral, or cardiac complications.

### Discussion

This case report presents a combined effort involving communication and timing of anesthetic interventions in response to a potentially serious complication. The fact that the patient survived without any complication was probably due to the combined protective effects of the following : 1) surgeon's skill; 2)proper timing; 3)packing the patient's head in ice; 4) the administration of pharmacological agents; 5)modified ultrafiltration (MUF) usage; and 6) retrograde cerebral perfusion (RCP) and selective antegrade cerebral perfusion (SACP). The following is an explanation about all of the above-mentioned points.

Circulatory arrest allows a bloodless and clean field during the repair of intimal tears, while avoiding clamp injury to a fragile dissected aortic tissue(4). An important complication of DHCA is neurological dysfunction. In humans, the safe period for strokes not developing appears to be limited to between 40minutes(5) and 60 minutes(6)following circulatory arrest.The incidence of temporary neurological dysfunction has been shown going up linearly in relation to the duration of hypothermic circulatory arrest(6).Svensson et al. (5) reported a stroke rate of 7%, and Ergin et al. (6) showed an embolic stroke rate of 11% and temporary neurological dysfunction rate of 19%. The mortality rate for emergency procedures would be higher because these patients would not have been properly evaluated preoperatively and would have had greater preoperative hemodynamic instability. Cardiopulmonary time is closely related to mortality and serious neurological deficit. Microembolization during prolonged CPB is likely to be a greater factor in the creation of stroke than

cerebrovascular ischemia time(7,8).A focal deficit is usually an embolic phenomenon, whereas a prolonged poor perfusion of the brain may produce necrosis in watershed zones.

Age, atherosclerosis, and manipulation of the aorta are risk factors for both(9). Global cerebral ischemia leads to diffuse neurological deficit, which maybe reversible or irreversible.

As was mentioned, risk factors for neurological deficit include increased duration of circulatory arrest and CPB, diabetes mellitus, and hypertension. Transient neurological dysfunction during DHCA appears to be a marker of long-term cerebral injury(10). The length of time on CPB might be a better predictor of postoperative death and stroke than the duration of DHCA time(5).

There are methods to provide brain protection: 1) pharmacologic protection and 2) non-pharmacologic protection.

### *Pharmacologic protection*

Many pharmacologic interventions have been proposed for organ protection during DHCA. Animal studies have suggested a beneficial effect of barbiturates, steroids, anticonvulsants, Lidocaine, calcium channel blockers, and antagonist, to the glutamate receptor subtypes.Barbiturates act by reducing the cerebral metabolism of oxygen ( $CMRO_2$ ),cerebral blood flow(CBF), free fatty acids, free radicals, cerebral edema, and seizure activity. Nussmeier et al.(12)were among the first to report the beneficial effects of thiopental in the prevention of neuropsychiatric complications after cardiac surgery(11). In global ischemia,barbiturates fail to play an important role in the outcome. Barbiturates have been shown to be protective in incomplete focal ischemia because of multiple emboli such as those seen during CPB (13). In addition, they may be helpful during rewarming after DHCA, especially in the early phase, when jugular venous oxygen desaturation shows decreased oxygen delivery(9).Steroids, particularly

dexamethasone and methylprednisolone, work against the systemic inflammatory response during and after CPB by decreasing pro-inflammatory cytokines, which are thought to play a role in brain ischemic injury as well as myocardial depression and  $\beta$ -adrenergic desensitization(9). High-dose steroid use may lead to increased risk of sepsis and an alternative in glucose metabolism. Magnesium has shown evidence of protection against hypoxia in the rat hippocampus(14). This can be explained by magnesium-induced blockade of both voltage-sensitive and NMDA-activated neuronal  $Ca^{++}$  channels. Mannitol is an osmotic diuretic that protects the kidney by lowering renal vascular resistance, preserving tubular integrity, and reducing endothelial cell edema. It also reduces cerebral edema and scavenges free radicals, thus reducing tissue damage(15).  $Ca^{++}$  ions play a major role in the ischemic cascade. Nimodipine is used for vasospasm prophylaxis after subarachnoid hemorrhage and has some efficacy in improving the cognitive outcome after CPB but it is associated with complications such as hypotension in patients undergoing valve replacement(14). Lidocaine blocks  $Na^+$  channels in neuronal membranes. In an animal study, high doses of Lidocaine induced isoelectric EEG and pronounced reduction in  $CMRO_2$  (16). Lidocaine mimics the effect of hypothermia. In a human study, a continuous infusion of Lidocaine (4mg/min) during and after CPB resulted in better short-term cognitive outcome(17). In general, the protective effects of Lidocaine need to be evaluated further(18). Hyperglycemia might worsen neurologic injury by increasing tissue lactic acidosis. Insulin has been shown to have a neuroprotective effect against such injuries (19). A retrospective analysis of patients undergoing aortic arch surgery revealed that hyperglycemia more than 250mg/dl was associated with an adverse neurological outcome(20). There are several drugs that have neuroprotective

effects during DHCA. However, there is currently no sufficient evidence to support the clinical use of this drug for neuroprotection during DHCA (Table1)(9).

Table1. Proposed Mechanisms of Action of Potentially Neuroprotective Pharmacologic Agents

Pharmacologic Agent	Proposed Mechanism
Barbiturates	Reducing $CMRO_2$ , CBF, free fatty acids, free radicals, and cerebral edema. Protective in focal ischemia.
Steroids	Decreasing proinflammatory response
Mannitol	Reducing cerebral edema, scavenging free radicals, protecting the kidneys by lowering renal vascular resistance, preserving tubular integrity, and reducing endothelial cell edema
Furosemide	Blocking renal reabsorption of sodium and increasing renal blood flow
Insulin	Controlling hyperglycemia, preventing intracellular acidosis
Calcium channel blocker	Blockade of voltage-sensitive and NMDA-activated neuronal $Ca^{++}$ channels, decreasing calcium influx into cytoplasm
Lidocaine	Selective blockade of $Na^+$ channels in neuronal membranes, reducing $CMRO_2$
Dexmedetomidine	Dexmedetomidine Inhibition of ischemia-induced norepinephrine release, protective in both focal and global ischemia
Remacemide	Glutamate antagonist
Acadensine	Mitigates the effects of reperfusion injury
$\beta$ – Blockers	Decreasing inflammatory response

### ***Non-pharmacologic protection***

To diminish cerebral ischemia time, selective perfusion of the brain during deep hypothermia has been implemented in the form of both retrograde cerebral perfusion(RCP) and antegrade cerebral perfusion(ACP).

ACP has been shown to achieve near-physiological brain perfusion with homogenous distribution of blood and may extend the safe time of circulatory

arrest(8). ACP could be hemispheric (through the right axillary subclavian or innominate artery) or bihemispheric (by adding the left common carotid artery). Advantages of ACP include a better ability to meet the demands of brain metabolism, flushing brain metabolic waste during ischemia, and better control of brain temperature. ACP may eliminate the need for deep hypothermia, thus reducing pump time(21). Disadvantages of ACP include risks of arterial wall dissection, malperfusion, embolism of atheromatous plaque or air, and cluttered operative field(9).

RCP is achieved by cannulating the superior vena cava. This method allows for deep and homogenous cooling of the brain and helps to flush solid particles, air bubbles, and metabolites from the arteries, thus reducing embolic phenomena and delaying the onset of acidosis in the ischemic brain. RCP has been reported to reduce mortality rates and stroke rates(22,23). The partial perfusion provided by RCP is insufficient to sustain cerebral metabolism, which might be impaired further with RCP-induced cerebral edema(24).

Some investigators have suggested the following strategies on the basis of the expected operative procedure and circulatory arrest time:

1) For limited arch replacement with short circulatory arrest time (30-40 minutes), DHCA alone would be sufficient.

2) For more extensive repairs that require prolonged circulatory arrest times, DHCA plus ACP is recommended.

3) For operations with high embolic risk, DHCA plus RCP is recommended (25) (Table 2)(9).

Table 2- Comparative Characteristics of ACP and RCP as Adjunctive Methods of Cerebral Protection

Characteristics	ACP	RCP
Simplicity and ease of application	--	+
Adequacy to support cerebral metabolism	++	-
Reduced pump time	+	--
Limited manipulation of arch branches	--	++
Reduced embolic load	--	++
Risk of arterial wall dissection, malperfusion, embolism	++	--
Interstitial edema, cerebral edema	-	++
NOTE. + and - indicate degree of presence or absence, respectively.		

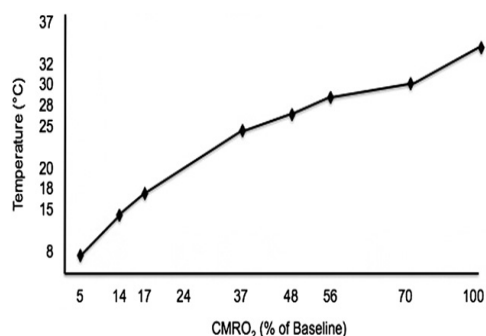
### **Hypothermia**

Hypothermia is firmly and justifiably established as the principle cerebral protective technique for circulatory arrest procedures. Hypothermia may attenuate the effect of cerebral ischemia by creating a favorable balance between oxygen supply and demand and by decreasing the cerebral metabolic rate of oxygen (CMRO<sub>2</sub>). Hypothermia not only reduces the metabolic rate but also delays the release of excitatory amino acids, neurotransmitters that play an important role in the process of neuronal death(26). Additionally, hypothermia reduces the permeability of brain arterioles and prevents blood-brain-barrier dysfunction(27). Hypothermia may also interfere with the inflammatory response by suppressing the adhesion of polymorphonuclear leukocytes in the damaged region(28). The reduction in CMRO<sub>2</sub> with hypothermia is about 7% in every 1°C decreasing of temperature. Between 37°C and 22°C, CMRO<sub>2</sub> is reduced by about 5% in every 1°C decreasing, and then the reduction

accelerates when  $CMRO_2$  reaches 20% at 20°C and 17% at 18°C (Figure2)(29).

Additional mechanisms of hypothermia include halting the ischemic injurious cascade, reducing glutamate excitotoxicity, suppressing intracellular calcium influx, decreasing formation of oxygen free radicals, and increasing gamma-aminobutyric acid release(30).

Figure2- The effect of temperature on  $CMRO_2$



### Topical (head) cooling

Ice packing of the skull enhances cerebral hypothermia via conduction across the skull(31). Ice packing the head, in addition to keeping the body temperature around 10°C to 13°C, also might help prevent an undesirable rewarming of the brain during DHCA. An animal study showed an improved behavioral outcome with head ice packing during DHCA(32).

### MUF

The process of MUF(modified ultrafiltration) is important for the recovery of normal cerebral function; care must be exercised not to negate the benefits by decreasing the time on MUF by increasing the flow rates. MUF also improves CBF and increases cerebral metabolic activity and cerebral oxygen delivery after DHCA. This latter effect acutely improves cerebral metabolism after DHCA and may reduce and reverse the known deleterious effects of DHCA on the brain function after CPB(33).

### DHCA

DHCA is an established technique that is used during the surgical repair of the aortic

arch and other major vessels. Regardless of the degree of hypothermia or circulatory arrest, DHCA provides the convenience of a bloodless surgical field, whereas deep hypothermia provides significant protection to the brain and other major organs against circulatory arrest. Advances in monitoring cerebral and other organ functions and in pharmacologic and non-pharmacologic therapeutic interventions continue to provide tools for improving the outcome of care of patients with complex vascular lesions.

### References

1. Griep RB, Stinson EB, Hollingsworth JF, Buehler D. Prosthetic replacement of the aortic arch. *J Thorac Cardiac Surg*; 1975;70:1051-63.
2. SY Chong, MYH Chow, DSC Kang, YK Sin, EKW Sim, LK Ti. DHCA in Adults Undergoing Aortic Surgery. *Annual Academy of Medicine*; may 2004, Vol 33, No.3.
3. Okita Y, Minatoya K, Tagusari O, Ando M, Nagatsuka K, Kitmura S. Prospective comparative study of brain protection in total aortic arch Replacement : deep hypothermic circulatory arrest with retrograde cerebral perfusion or selective antegrade cerebral perfusion. *Ann ThoracSurg* 2001 ; 72 :72-9.
4. Sinatra R, Melina G, Pulitani I, Fiorani B, Ruvolo G, Marino B. Emergency operation for acute type A aortic dissection : neurologic complication and early mortality. *Ann ThoracSurg* 2001 ; 71 : 33-8.
5. Svensson LG, Crawford ES, Hess KR, Coselli JS, Raskin S, Shenaq SA, et al. Deep Hypothermia with circulatory arrest. Determinants of

- stroke and early mortality in 656 patients. *J Thorac Cardiovasc Surg* 1993 ; 106 : 19-31.
6. Ergin MA, Galla JD, Lansman L, Quintana C, Bodian C, Griep RB. Hypothermic circulatory arrest in operations on the thoracic aorta. Determinants of operative mortality and neurologic outcome. *J Thorac Cardiovasc Surg* 1994 ; 107 : 788-99.
  7. Goldstein LJ, Davies RR, Rizzo JA, Davila JJ, Cooperberg MR, Shaw RK , et al. Stroke in surgery of the thoracic aorta : incidence, impact, etiology and prevention. *J Thorac Cardiovasc Surg* 2001 ; 122 : 935-45.
  8. Chong SJ, Chow MJ, Kang DS, et al : Deep hypothermic circulatory arrest in adults undergoing aortic surgery. Local experience. *Ann Acad Med Singapore* 2004 ; 33 : 289-293.
  9. Marina Sryatets, Kishore Tolani, Mingzhang, Gene Tulman, Jeen Charchafieh. Perioperative management of deep hypothermic circulatory arrest. *Journal of cardiothoracic and vascular Anesthesia* 2010 ; vol 24, 644-655.
  10. Ergin MA, Uysal S, Reich DL, et al: Temporary neurological dysfunction after deep hypothermic circulatory arrest : A clinical marker of long-term functional deficit. *Ann Thorac Surg* 67 : 1997;1890,1899.
  11. Nussmeier NA, Arlund C, Slogoffs :neuropsychiatric complications after cardiopulmonary bypass : cerebral protection by a barbiturate. *Anesthesiology* 1986; 64 : 165-170.
  12. Brain Resuscitation clinical Trial 1 study group: a randomized clinical study of thiopental loading in comatose survivors of cardiac arrest. *N Engle J Med* 1986;314: 397-403.
  13. Dewhurst AT, Moore SJ, Liban J B: Pharmacological agent as cerebral protections during deep hypothermic circulatory arrest in adult thoracic aortic surgery. A survey of current practice *Anesthesia* 2002;57 : 1016 – 1021.
  14. Kass Is, Cottrell JE, Chambers G : Magnesium and Cobalt, not nimodipine, protect neurons against anoxic damage in the rat hippocampal slice. *Anesthesiology* 1988; 69 : 710-715.
  15. Yang MW, Lin CY, Hung HL, et al: mannitol reduces plasma hydrogen peroxide free radical in patients undergoing coronary artery bypass graft surgery. *Ma ZuiXueZaZhi* 1992;30:65-70.
  16. Zhou Y, Wang D, Du M, et al: Lidocaine prolongs the safe duration of circulatory arrest during deep hypothermia in dogs. *Ca J Anesth* 1998; 45 : 692-698.
  17. Wang D, Wux, Li J, et al : The effect of lidocaine on early postoperative cognitive dysfunction after coronary artery bypass surgery. *Anesth Analg* 2002; 95 : 1134-1141.
  18. Mathew HP, Mackensen GB, Philips- Bute B, et al : Randomized double-blind, placebo controlled study of neuroprotection with lidocaine in cardiac surgery. *Stroke* 2009; 40 : 880-888.
  19. Strong AJ, Fairfield JE, Moniteiro E, et al : Insulin protects cognitive

- function in experimental stroke. *J Neurol Neurosurg Psychiatry* 1990; 53 :847-853.
20. Ceriana P, Barzaghi N, Locatelli A, et al: Aortic arch surgery : Retrospective analysis of outcome and neuroprotective strategies. *J Cardiovasc (Torino)* 1998;39 : 337-342.
  21. Kaneda T, Saga T, Onoe M, et al: Antegrade selective cerebral perfusion with mild hypothermic systemic circulatory arrest during thoracic aortic surgery. *Sand cardiovasc J* 2005;39:87-90.
  22. Coselli JS, Le Maire SA : Experience with retrograde cerebral perfusion during proximal aortic surgery in 290 patients. *J car Surg* 1997; 12 : 322-325 (suppl).
  23. Sati HJ, Letsou GA, Llipoulos DC, et al : Impact of retrograde cerebral perfusion on ascending aortic and arch aneurysm repair. *Ann Thorac Surg* 1997; 63 : 1601-1607.
  24. Bechtel JFM, Eleftheriadis S, Sievers HH: Surgical strategies for neuroprotection during ascending aortic arch surgery. *APPL Cardiopulm Pathophysiol* 2009; 13 : 219-223.
  25. Svensson LG: Antegrade perfusion during suspended animations. *Thorac Cardiovasc Surg* 2002; 124: 1068-1070.
  26. Fujisawa H, Koizumi H, Ito H, et al : Effects of mild hypothermia on the cortical release of excitatory amino acids and nitric oxide synthesis following hypoxia. *J Neurotrauma* 2002; 16 : 1083 – 1093.
  27. Dietrich WD, Busto R, Halley M, et al: The importance of brain temperature in alterations of the blood-brain-barrier following cerebral ischemia. *J Neuropathol EXP Neurol* 1990; 49:486-497.
  28. Chen Z, Chen H, Rhee P, et al Induction of profound hypothermia modulates the immune/inflammatory response in a swine model of lethal hemorrhage: Resuscitation 2005;66:209-216.
  29. Kimura T, Muraoka R, Chiba Y, et al : Effect of intermittent deep hypothermia and circulatory arrest on brain metabolism. *J Thorac Cardiovasc Surg* 1994; 108:658-663.
  30. Dorotta I, Kimball-Jones p. applegate R: Deep hypothermia and circulatory arrest in adults. *Semincardiothorac Vasc Anesth* 2007; 11:66-76.
  31. Malatanis G, Hata M, Buxton BF: A retrospective comparative study of deep hypothermic circulatory arrest, retrograde and antegrade cerebral perfusion in aortic arch surgery. *Ann Thorac Cardiovasc Surg* 2003 9;174-179.
  32. Griep RB, Ergin MA, MC Cullough JN, et al: Use of hypothermic circulatory arrest for cerebral protection during aortic surgery. *J Card Surg* 1997; 12:312-321.
  33. Skaryak LA, Kirshbom PM, Di Bernardo LR, et al: Modified Ultrafiltration improves cerebral metabolic recovery after circulatory arrest. *J Thorac Cardiovasc Surg* 1995;109:744.