
Case Reports

Malignant Melanoma in the Heart, With Focus on the Histopathological Diagnosis: Review of Our Two Cases in a Five-Year Period

Kambiz Mozaffari * MD, Niloufar Samiei MD, Safarali Abdolrahimi MD

Abstract

Over a five-year period, we encountered two cases of malignant melanoma with metastasis to the heart and pericardium. Both patients had a relevant medical history, showing their previous involvement by this tumor. A high index of suspicion, simply provided by a precise clinical history, together with histopathological and cytological studies can be used to diagnose such patients in due course. The preliminary diagnosis is made by echocardiography, by which the tumoral masses are seen in different parts of the heart. Nevertheless, their primary or secondary origin as well as the histogenesis can only be ascertained by pathological studies.

Routine staining methods are useful in the demonstration of malignant cells in the tissue or pericardial fluid samples (*Iranian Heart Journal* 2011; 12 (1):50 -52).

Keywords: Malignant melanoma ■ metastasis ■ Heart ■ Pericardium

Archive of SID

Cardiac metastases are more frequent than are primary tumors and generally have a worse prognosis. Malignant melanoma is well known to have a propensity to metastasize to the heart. Patients may present with multiple or single nodular masses in the heart chambers as well as bloody effusions that may lead to cardiac tamponade. Here, we describe two patients who had malignant melanoma in their past medical histories, together with neurological and lymph node metastases. In such patients, transthoracic and transesophageal echocardiography studies offer the preliminary diagnosis, but the histogenesis can only be ascertained by histopathological examinations.

Case Reports

1. A 51-year-old female presented with symptoms of quadriplegia. She had a brain tumor about four months prior to this admission, for which she had undergone surgery.

The histopathological diagnosis was compatible with metastatic malignant melanoma. Twenty days after the brain surgery, she came to seek medical attention for quadriplegia.

The magnetic resonance imaging (MRI) revealed involvement of cervical and lumbar epidural spaces. In order to decompress the patient's spinal cord, which sustained the pressure effects of the tumor, our neurosurgeon decided to schedule her for surgery and therefore requested a cardiology consultation.

Received Feb. 2, 2010; Accepted for publication Jan. 9, 2011

Correspondence to: Kambiz Mozaffari, M.D., Surgical Pathology Laboratory, Shaheed Rajaie Cardiovascular, Medical and Research Center, Mellat Park, Vali Asr Ave., Tehran, Iran.

Tel: 23921

Transthoracic and transesophageal echocardiography studies were performed; and multiple mobile, homogeneous and well-defined masses were noted.

A pedunculated mass, originating from the base of the interatrial septum, was detected in the left atrium. A second one was found near the base of the anterolateral papillary muscle in the left ventricle, and two other large masses were in the right atrium, with the latter producing a significant obstructive effect on the tricuspid valve. There was also a mild pericardial effusion.

The patient underwent an operation to remove the masses. The histopathological diagnosis of the excised neoplastic tissues was metastatic malignant melanoma.

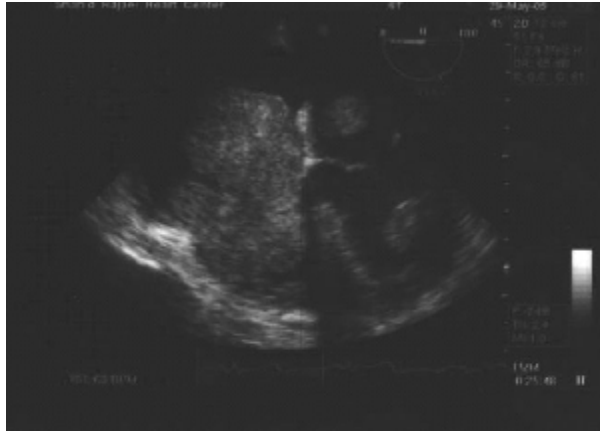


Fig.1. Multiple tumoral masses in the right atrium protruding into the other three chambers

2- A 61-year-old man was referred to our hospital with a chief complaint of recent-onset dyspnea and chest pain. Further workup revealed a pericardial effusion, which was bloody in appearance. Three years prior to his admission, he had undergone a surgical operation for the excision of a malignant skin tumor from the sole of his foot. A recurrence of the tumor had involved his inguinal lymph node the previous year. During these episodes, he received regular chemotherapy treatment for the neoplasm.

The cytological examination of the pericardial fluid revealed a bloody background with clusters and nests of malignant cells. The tumoral cells had a high nucleocytoplasmic (N/C) ratio and moderate pleomorphism. Their cytoplasmic spaces were laden with coarse and fine dark brown melanin pigment. A tiny piece of pericardial tissue was also sent to the pathology ward for examination, which showed the above-mentioned cells in the microscopic samples.

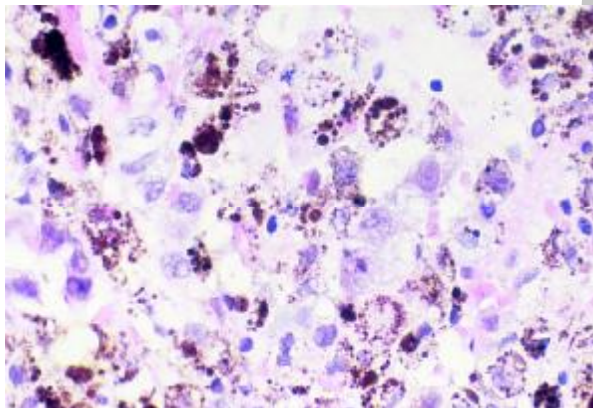


Fig. 2. Metastatic malignant melanoma cells in the pericardial fluid (Giemsa method X 400)

Discussion

Metastasis to the heart and pericardium is much more frequently encountered than is the case with primary cardiac tumors. Generally, secondary tumors carry a poorer prognosis.^{1,2,3}

Lung and breast cancers, malignant melanoma and lymphomas are the most likely primary invaders affecting the heart and pericardium.^{1,4,5}

The preliminary diagnosis is made by echocardiography, by means of which the tumoral masses are seen in different parts of the heart. Nonetheless, their primary or secondary origin as well as the histogenesis can only be verified by histopathological studies.

Malignant melanoma, a neoplasm with a dismal prognosis due to its propensity to metastasize early with possibly few symptoms, typically produces bulky lesions.

Malignancies occurring in the pericardial sac often cause a bloody effusion but can be reliably diagnosed by cytological examination of the fluid.⁶

Acknowledgments

We wish to thank Mr. Farshad Amouzadeh for his technical assistance.

References

1. Samiei N, Moshkani Farahani N, Sadeghipour A, Mozaffari K, and Maleki M: Intracardiac metastasis of malignant melanoma. *European Journal of Echocardiography* (2008) 9, 393–394.
2. Lam KY, Dickens P, Chan ACL. Tumors of the heart: a 20-year experience with a review of 12,485 consecutive autopsies. *Arch Pathol Lab Med* 1993; 117:1027–31.
3. Mukai K, Shinkai T, Tominaga K, Shimosato Y. The incidence of secondary tumors of the heart and pericardium: a 10-year study. *Jpn J Clin Oncol* 1988; 18: 195–201.
4. Abraham KP, Reddy V, Gattuso P. Neoplasms metastatic to the heart: review of 3314 consecutive autopsies. *Am J Cardiovasc Pathol* 1990; 3:195-8
5. Klatt EC, Heitz DR. Cardiac metastases. *Cancer* 1990; 65: 1456–9.
6. Silver MD, Gotlieb AI, Schoen FJ. *Cardiovascular Pathology*. 3rd edition, New York, Churchill Livingstone Company, 2001; p.600.