

## Anterior Leaflet Augmentation: an Effective Method to Repair Tricuspid Valve Regurgitation

Saeid Hosseini MD, Faranak Kargar MD, Mehdi Hadadzadeh MD, Bahram Hashemzadeh MD, Kamal Raissi MD, Anita Sadeghpour\* MD, Niloufar Samiei\* MD, Mohammad Hasan Kalantar Motamedi MD, Mohammad M. Peighambari MD, Feridoun Noohi\*MD, FACC

### Abstract

**Objectives-** As an invaluable surgical tool, autologous pericardium has been successfully used to repair many cardiac lesions. The encouraging results from its use in repairing heart valves have been applied to repair tricuspid valve regurgitation (TR). In the present study, we report our preliminary results using autologous pericardium as an alternative surgical technique in repairing tricuspid valve insufficiency.

**Methods-** From June 2002 to November 2006, 22 patients (mean age 39.7 years) with heart valve disease underwent tricuspid valve repair by anterior leaflet augmentation with glutaraldehyde-treated autologous pericardium. Nineteen patients (86.4%) had pure tricuspid valve regurgitation (TR), while the remaining three patients (13.6%) had significant associated tricuspid valve stenosis in whom commissurotomy was carried out. TR was considered severe in 18 patients and moderate to severe in four cases. All had associated left-sided heart valve surgery, except two patients. Concomitant adjustable tricuspid annuloplasty by pericardial band was performed in 12 patients. The mean follow-up period was 10.39 months (range 1 to 42 months).

**Results-** There was one in-hospital death due to postoperative multiorgan failure. One patient developed partial detachment of the pericardial patch, which was successfully repaired. Echocardiography data showed a significant decrease in the severity of TR: trivial to mild in 68.2% ( $n=15$ ), mild to moderate in 22.7% ( $n=5$ ), and moderate to severe in 9.1% ( $n=2$ ) of the patients.

**Conclusions-** Anterior tricuspid leaflet augmentation is a safe, effective and appealing surgical technique in dealing with patients with tricuspid valve regurgitation. Further studies are, however, mandatory to evaluate its long-term outcome (*Iranian Heart Journal 2010; 11 (2):6-13*).

**Key words:** tricuspid valve repair ■ pericardial augmentation ■ tricuspid valve insufficiency

---

**F**or decades, the concept of repairing tricuspid valve regurgitation (TR) has made no significant headway, except for work on its annulus, and residual or recurrent tricuspid regurgitation after current valve repairing procedures are common.<sup>1-8</sup> Annular undersizing or stabilizing (either ring or suture-based) and bicuspidization are the two

main technical methods utilized in addressing functional TR.<sup>1, 2, 9</sup> Nevertheless, the actual reported rates of procedure-related repair failure and residual evolving TR speak to our incomplete understanding of its underlying pathogenesis and the subsequent influence of postoperative hemodynamic conditions on the stability of the repaired tricuspid valve.

---

Received Dec. 23, 2009; Accepted for publication Jun. 12, 2010

From the Department of Cardiovascular Surgery and Cardiology\*, Shaheed Rajaie Cardiovascular Medical and Research Center, Tehran, Iran.

Corresponding Author: Saeid Hosseini MD, Cardiac Surgery Department, Shaheed Rajaie Cardiovascular Medical and Research Center, Tehran, Iran.

Email: [saeid.hosseini@yahoo.com](mailto:saeid.hosseini@yahoo.com)

Telefax: +98 21 - 220 420 37

The perception that residual evolving TR may be associated with poor clinical outcome and the considerable attrition sustained by the reoperation as well, have stimulated attempts at further investigating this “parent-pauvre” of heart valve surgery in the past years, yet without any solid development in the available surgical armamentarium. The forgotten role of the subvalvar apparatus in the pathogenesis of tricuspid valve regurgitation, annuloplasty failure and postoperative recurrence of TR has been recently brought to the surface.<sup>5,10,11</sup> It is sobering that functional tricuspid regurgitation should present the same level of complexity as is the case with ischemic mitral regurgitation, while suffering the same technical shortcomings and even worse operative results than the latter when using annular undersizing.<sup>4-6,8</sup> Leaflet augmentation using the pericardium has been advocated as a valuable method, lending itself well to address diverse types of mitral and congenital tricuspid valve regurgitation, as well repairing endocarditic lesions. This approach seems to have withstood the test of time, gaining acceptance in circumstances where subvalvar and annular dilation participate in mitral valve regurgitation, especially in rheumatic involvement.<sup>12-14</sup> In line with the latter approach as suggested by Dreyfus<sup>4</sup>, we have set out to implement the technique of anterior leaflet augmentation in the setting of functional and organic-functional tricuspid regurgitation, and here we report our early surgical results.

### Methods

From June 2002 to November 2006, 22 patients underwent tricuspid valve repair for functional or organic-functional tricuspid regurgitation with the current technique at our center. Preoperative, perioperative and postoperative data were entered prospectively into a computerized database. The study was approved by the institution’s Research Ethics Board. Written informed consent was

obtained from all patients. Preoperative trans-thoracic and transesophageal (TEE) color-duplex echocardiography was performed to assess the severity of tricuspid valve regurgitation, the pathology of left-sided heart valves, left ventricular functional class, and right ventricular pressures. Cardiac catheterization was not performed routinely unless patient risk factors indicated the need for studying the coronary arteries. Assessment of repair was carried out by means of perioperative TEE. Echocardiograms were performed routinely before discharge and during follow-up. The patients were followed up at our out-patient department at 30 days and 6 months after operation and annually thereafter. Postoperative events were compiled and analyzed according to the guidelines for reporting morbidity and mortality after cardiac valvular operations.

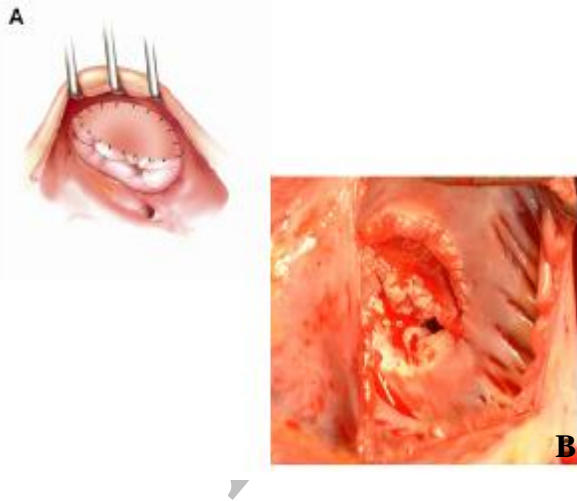
### Operative technique

After median sternotomy, the pericardium was opened longitudinally through a right-sided incision in view of harvesting a large pericardial patch to be treated with glutaraldehyde, 0.6% for 10 minutes. The operation was carried out on cardiopulmonary bypass (CPB) and using cold blood cardioplegia for myocardial protection and with bi-caval cannulation as part of the right atrial isolation. After completion of the left-sided valve surgery or CABG, the right atrial wall was opened obliquely near the atrio-ventricular groove. The anterior leaflet and anterior half of the posterior leaflet was then detached from its annular insertion (Fig. 1, A-C). We leave about 2 mm of the leaflet for better suturing of the pericardial patch. The pre-treated pericardial patch is then tailored in a large, oval-shaped fashion to fit the defect and sewn in place by means of locked continuous running sutures using two separate polypropylene 5/0 or 4/0 sutures (Fig. 2, A, B). After completion of the procedure, valve competency was analyzed by distending the right ventricle with saline solution. After

weaning from CPB, TEE was done for all cases.



**Fig.1.** **A**, operative drawing showing the line of the anterior and posterior leaflets detachment, **B**, operative drawing showing the defect to be patched, **C**, operative view: the anterior and posterior leaflets are detached; note the large resultant defect.



**Fig. 2.** **A**, operative drawing depicting the oval-shaped pericardial patch sutured to the annulus and the anterior and posterior leaflet of the tricuspid valve, **B**, operative view showing final result.

## Results

Twenty-two patients were included in the study, eight male (36.4%) and 14 female

(63.6%), mean age was 39.73 (range: 16-62) years old. Preoperative New York Heart Association Class was II in 11 patients (50%), III in 5 patients (22.7%) and IV in 6 patients (27.3%, Table I).

**Table I. Patient characteristics**

Age (year)	39.73 (range 16 - 62)
Female	14 (63.3%)
Preop NYHA class II	11 (50%)
III	5 (22.7%)
IV	6 (27.3%)
Pure tricuspid regurgitation	19 (86.4%)
Mixed tricuspid disease	3 (13.6%)
Concomitant surgery	20 (91%)
MVR	11
MVR + AVR	5
OMVC	1
MVR+CABG	1
MVR+ AV repair	2

AVR: aortic valve replacement, CABG: coronary artery bypass grafting, OMVC: open mitral valve commissurotomy, MVR: mitral valve replacement

Preoperative echocardiography showed severe TR in 18 patients (81.8%) and moderate TR in 4 patients (18.1%, Table II). Nineteen patients (86.4%) had pure tricuspid valve regurgitation, while the remaining three patients (13.6%) had significant associated tricuspid valve stenosis, in whom commissurotomy was carried out as well. Except for two patients (9.1%), all underwent concomitant surgery, comprising open mitral valve commissurotomy (n=1), mitral valve replacement (n=11), aortic valve replacement + mitral valve replacement (n=5), mitral valve replacement + aortic valve repair (n=2) and mitral valve replacement + coronary artery bypass grafting (n=1). Concomitant adjustable tricuspid annuloplasty by pericardial band was performed in the last 12 patients (54.5%). There was one in-hospital death due to postoperative multi-organ failure. One patient developed partial detachment of the pericardial patch two weeks after the first

operation, which was successfully repaired. At the time of discharge, one patient had moderate and the remaining 20 (95%) patients presented with mild residual TR (Table II).

**Table II. Pre- and post-operative tricuspid valve regurgitation severity by echocardiography**

TR Severity	Pre-op	Discharge	F/U
<i>Mild</i>	0	15	8
<i>Mild to Moderate</i>	0	5	8
<i>Moderate</i>	4	1	3
<i>Severe</i>	18	0	2
<i>Total</i>	22	21	21

Follow-up was 100% complete among the survivors and the mean follow-up period was 10.39 months (range, 1 - 42 months). The most recent postoperative echocardiography study showed no detectable TR in four patients, grade 1 in 15 patients, grade 2 in one patient and grade 3-4 in the remaining one. Tricuspid stenosis was reported only in one patient (4.5%) who had moderate stenosis preoperatively.

### Discussion

The proper management of TR remains a clinical challenge, both in terms of operative indication and the accurate surgical technique to be employed.<sup>1-4,8,15,16</sup> Recent studies have highlighted the self-perpetuating and progressive nature of surgically untreated TR, and the salient points are to preoperatively evaluate the potential risk of the postoperative occurrence of worsening TR and to implement the proper repair technique at the time of left-sided valve surgery. Matsunga and Duran reported a rate of 53% (10/19) of patients having greater than 2+ TR at 3 years after mitral valve repair alone.<sup>17</sup> Similarly, Matsuyama et al. have recently reported that 37% (17/46) of their patients with preoperative TR greater than 2+ have 3+ or 4+ tricuspid regurgitation at 8 years after

mitral valve surgery alone.<sup>18</sup> Dreyfus et al. showed annular dilatation more than 21 mm/m<sup>2</sup> as a potential risk factor predisposing to the occurrence of postoperative TR; thereby recommending prophylactic tricuspid annuloplasty at the time of left-side valve surgery (LSVS) in order to abort the self-perpetuating potential of TR postoperatively.<sup>19</sup> The available body of evidence suggests a more aggressive approach towards TR at the time of the left-sided heart valve surgery, despite the fact that any direct relation between the persistent TR and patient functional class and survival has not yet been formally demonstrated.<sup>2,4,8,15,20,21</sup> Therefore, the question as to whether the latter may affect the patient outcome supports the current attitude along which addressing TR at the time of surgery is of intrinsic importance.

When it comes to the surgery, repair procedures have gained wider acceptance in comparison to tricuspid valve replacement (TVR), in view of the poor outcome and considerable morbidity carried by TVR.<sup>2,22</sup> The mainstay of repairing procedures concerns the tricuspid annulus in an expedited manner, imposing on the tricuspid valve apparatus what is thought to be the key solution for the mitral valve without, however, taking into consideration the huge differences existing in pathophysiology of these two entities. Meanwhile, tricuspid regurgitation is common after annuloplasty, and can be classified in three categories: residual tricuspid regurgitation, early, and late TR recurrence. The former is seen as a methodological flaw to address TR, while the latter two would witness the inefficacy of annuloplasty, facing the postoperative worsening potential of TR in terms of repair stability over time. Whatever the annuloplasty technique used, the rate of early and late severe residual tricuspid regurgitation varies from 8 to 14% and 25 to 31%, respectively,<sup>2,4,6,20,23</sup> providing less than perfect surgical results in comparison to that obtained from mitral valve repair, even for functional ischemic mitral regurgitation. It is

unknown whether recurrent tricuspid regurgitation led to subsequent worsening of heart failure symptoms in patients in late follow-up or whether patients developed heart failure from progressive left ventricular dysfunction, with secondary pulmonary hypertension and right ventricular dysfunction that then led to tricuspid regurgitation. Moreover, reoperation for tricuspid regurgitation is rare, despite the return of many patients to NYHA class III or IV. The low rate of reoperation may be due in part to the perception that this is a high-risk procedure that may suggest a poor prognosis. As a result, reports defining success of annuloplasty as freedom from reoperation should be viewed cautiously.<sup>4</sup> In addition, symptomatic patients might have been more likely to receive follow-up echocardiography than asymptomatic ones, undermining the actual prevalence of recurrent TR.

There is no consensus as to which method of annuloplasty offers a more stable repair over time.<sup>2,4,5,6,15,24,25</sup> The suture-based and segmental band annuloplasty techniques are seen as offering lesser stability over time than semi-rigid ring annuloplasty, despite the economic aspects of the former. A prospective, randomized study of 159 patients conducted by Rivera et al. comparing the De Vega suture to Carpentier ring annuloplasty demonstrated a higher recurrence of moderate and severe TR in the De Vega group at 45-month follow-up.<sup>5</sup> In a study of 790 patients who underwent TV repair for secondary TR, McCarthy et al. reported an earlier recurrence and progressive increase of moderate and severe TR after pericardial and De Vega suture repairs.<sup>4</sup> Similarly, in the study of Tang et al. 36% of survivors operated on with De Vega technique displayed moderate to severe TR in the late follow-up, as compared to 30% of those who had received a ring annuloplasty.<sup>2</sup> These findings suggest that an annuloplasty ring is recommended in patients undergoing TV repair, particularly in those with more severe TR, to avoid further recurrence and adverse long-term sequelae.

Aside from the above-mentioned uncertainty about the annuloplasty technique, rare studies have recently been undertaken to determine the risk factors for residual and occurrence of postoperative TR after diverse types of annuloplasty. Antunes, an advocate of the modified De Vega annuloplasty, attributed the occurrence of postoperative TR to "restriction-dilatation" syndrome, resulting from a complex hemodynamic interplay sustained by postoperative changes in intrapericardial pressures.<sup>15</sup> The echocardiography investigations have pointed out the role of the subvalvar component in the genesis of TR attributed to the tenting effect that can postoperatively be worsened by annular reduction per se.<sup>3,10</sup> In the study of McCarthy et al. most indicators of early worsening were markers of patient disease and as such could not be altered by the type of annuloplasty.<sup>4</sup> Interestingly, the authors demonstrated that the size of the Carpentier-Edwards ring or Cosgrove-Edwards band did not influence evolution of regurgitation over time. Other risk factors for the recurrence of TR over time have been identified as being higher preoperative grade of TR, left ventricular dysfunction and the need of inserting a pacemaker lead that is procedure unrelated.<sup>4</sup>

Compounding these data is the fact that the pathophysiology of TR is more complex than allowing it to only be addressed at the annular level. A matter of concern in dealing with correction of TR is the strong feeling of the need for emergence of newer techniques, which take into consideration the whole pathophysiology of tricuspid valve regurgitation.<sup>10</sup> Tricuspid valve regurgitation may sustain a similar pathophysiology as functional ischemic mitral regurgitation in which annular dilatation / deformation acts in concert with subvalvar apparatus dysfunction/asynchrony. Nevertheless, the functional complexity of the tricuspid valve apparatus hinders a direct approach towards its correction, as what has been suggested for ischemic mitral valve regurgitation.

The pericardium has been successfully used in heart valves reconstructive / repairing procedures as an invaluable tool in the surgical armamentarium, for it enables us to address a myriad of congenital and acquired heart valve diseases. The pericardium has been successfully used in repairing mitral valve regurgitation caused by leaflet retraction and sustained by rheumatic disease or after mediastinal radiotherapy.<sup>12,13</sup> Recently, leaflet augmentation has been proposed as an alternative technique to alleviate mitral leaflet restriction in the setting of ischemic mitral regurgitation.<sup>14</sup> In this line of reasoning along with encouraging reported results of leaflet augmentation in the field of mitral valve repair, the present technique is advocated to palliate the major components of the functional or organic-functional TR resulting in leaflet mal-coaptation. Patching the anterior tricuspid leaflet compensates, at least partially, for annular dilatation while reducing the tenting effect on the leaflet by central displacement of the chorda, and overcoming the leaflet retraction. In our series with the current technique, the rate of technical failure was 4.25% (1 patient), that was related to tearing of the anterior leaflet using simple continuous running sutures, a technical issue that thereafter was overcome by using locked continuous running sutures using two separated monofilament stitches. Among the survivors, 95% of the patients had mild and one patient (4.5%) had moderate residual TR at discharge. Overall, the rate of recurrence from moderate to severe TR over a mean period of follow-up of 10.53 months was 9% (two patients), and concerned the early phase of this study at which time segmental band annuloplasty was not carried out in addition to leaflet augmentation. The results of the present technique are more gratifying than the above-mentioned results already reported with various types of annuloplasty in terms of residual and recurrent postoperative TR. Nevertheless, these results should be further investigated in

a larger population and with longer follow-ups.

### Conclusion

In conclusion, our preliminary results using leaflet augmentation in addition to annuloplasty are encouraging, offering an integrated surgical approach to the complex pathophysiology of tricuspid valve regurgitation. Nevertheless, the current technique, being in its infancy, needs to stand the test of time in terms of long-term stability of the repaired tricuspid valve. Being aware of the importance of annular remodeling and stabilization as a crucial component of repair procedures, it is hoped that our results would be optimized by using a semi-rigid annuloplasty ring.

### Acknowledgments

We would like to thank Miss A. Someaneshin and Mr. P. Amouzadeh for their respective assistance in preparing the iconography and reviewing of this manuscript.

### Conflict of Interest

No conflicts of interest have been claimed by the authors.

### References

1. Cohn LH. Tricuspid regurgitation secondary to mitral valve disease: when and how to repair. *J Card Surg* 1994; 9: 237-241.
2. Tang GH, David TE, Singh SK. Tricuspid valve repair with an annuloplasty ring results in improved long-term outcomes. *Circulation* 2006; 114: 577-581.
3. Fukuda S, Song JM, Gillinov AM. Tricuspid valve tethering predicts residual tricuspid regurgitation after tricuspid annuloplasty. *Circulation* 2005; 111: 975-979.
4. McCarthy PM, Bhudia SK, Rajeswaran J. Tricuspid valve repair: durability and risk factors for failure. *J Thorac Cardiovasc Surg* 2004; 127: 674-685.

5. Rivera R, Duran E, Ajuria M. Carpentier's flexible ring versus De Vega's annuloplasty: a prospective randomized study. *J Thorac Cardiovasc Surg*. 1985; 89: 196–203.
6. Antunes MJ, Girdwood RW. Tricuspid annuloplasty: a modified technique. *Ann Thorac Surg* 1983; 35: 676–678.
7. Katircioglu SF, Yamak B, Ulus AT, Ozsoyler I, Yildiz U, Mavitas B, Birincioglu L, Tasdemir O. Treatment of functional tricuspid regurgitation by bicuspidalization annuloplasty during mitral valve surgery. *J Heart Valve Dis* 1997; 6: 631–635.
8. Frater R. Tricuspid insufficiency. *J Thorac Cardiovasc Surg* 2001; 122: 427-9.
9. Ghanta R, Chen R, Narayanasamy N, McGurk S, Lipsitz S, Chen FY, Cohn LH. Suture bicuspidization of the tricuspid valve versus ring annuloplasty for repair of functional tricuspid regurgitation: Mid-term results of 237 consecutive patients. *J Thorac Cardiovasc Surg* Jan 2007; 133: 117 - 126.
10. Fukuda S, Gillinov AM, McCarthy PM, Matsumura Y, Thomas JD, Shiota T. Determinants of recurrent or residual functional tricuspid regurgitation after tricuspid annuloplasty. *Circulation* 2006; 114[suppl I]: I-582–I-587.
11. Ton-Nu TT, Levine RA; Handschumacher MD, Dorer DJ, Yosefy C, Fan D, Hua L, Jiang L, Hung J. Geometric determinants of functional tricuspid regurgitation insights from 3-dimensional echocardiography. *Circulation* 2006; 114: 143-149.
12. Zegdi R, Khabbaz Z, Chauvaud S, Latremouille C, Fabiani JN, Deloche A. Posterior leaflet extension with an autologous pericardial patch in rheumatic mitral insufficiency *Ann Thorac Surg* 2007; 84: 1043 – 1044.
13. Aubert S, Flecher E, Rubin S, Acar C, Gandjbakhch I. Anterior mitral leaflet augmentation with autologous pericardium. *Ann Thorac Surg* 2007; 83: 1560-1.
14. Kincaid EH, Riley RD, Hines MH, Hammon JW, Kon ND. Anterior leaflet for ischemic mitral regurgitation. *Ann Thorac Surg* 2004; 78: 564-568.
15. Antunes MJ, Barlow JN. Management of tricuspid valve regurgitation. *Heart* 2007; 93: 271-276.
16. Breyer RH, McClenathan JH, Michaelis LL, McIntosh CL, Morrow AG. Tricuspid regurgitation. A comparison of nonoperative management, tricuspid annuloplasty, and tricuspid valve replacement. *J Thorac Cardiovasc Surg* 1976; 72: 867–874.
17. Matsunaga A, Duran CM. Progression of tricuspid regurgitation after repaired functional ischemic mitral regurgitation. *Circulation* 2005 Aug 30; 112 (9 Suppl): I453-7.
18. Matsuyama K, Matsumoto M, Sugita T, Nishizawa J, Tokuda Y, Matsuo T. Predictors of residual tricuspid regurgitation after mitral valve surgery. *Ann Thorac Surg* 2003; 75: 1826–1828.
19. Dreyfus GD, Corbi PJ, Chan KM, Bahrami T. Secondary tricuspid regurgitation or dilatation: which should be the criteria for surgical repair? *Ann Thorac Surg*. 2005 Jan; 79 (1): 127-32.
20. Mullany CJ, Gersh BJ, Orszulak TA, Schaff HV, Puga FJ, Ilstrup DM, Pluth JR, Danielson GK. Repair of tricuspid valve insufficiency in patients undergoing double (aortic and mitral) valve replacement: perioperative mortality and long-term (1 to 20 years) follow-up in 109 patients. *J Thorac Cardiovasc Surg* 1987; 94: 740–748.
21. Singh SK, Tang GH, Maganti MD, Armstrong S, Williams WG, David TE, Borger MA. Mid-term outcomes of tricuspid valve repair versus replacement for organic tricuspid disease. *Ann Thorac Surg* 2006; 82: 1735–4.
22. Scully HE, Armstrong CS. Tricuspid valve replacement. Fifteen years of experience with mechanical prostheses and bioprostheses. *J Thorac Cardiovasc Surg* 1995; 109: 1035–1041.
23. Kuwaki K, Morishita K, Tsukamoto M, Abe T. Tricuspid valve surgery for functional tricuspid valve regurgitation associated with left-sided valvular disease. *Eur J Cardiothorac Surg* 2001; 20: 577–582.
24. Onoda K, Yasuda F, Takao M, Shimono T, Tanaka K, Shimpo H, Yada I. Long-term follow-up after Carpentier-Edwards ring

annuloplasty for tricuspid regurgitation. *Ann Thorac Surg*. 2000 Sep; 70 (3): 796-9.

25. Bernal JM, Gutiérrez-Morlote J, Llorca J, San José JM, Morales D, Revuelta JM. Tricuspid valve repair: an old disease, a modern experience. *Ann Thorac Surg* 2004 Dec; 78 (6): 2069-74.

Archive of SID