

Determining the Frequency of Ventricular Dysfunction in Adult Congenital Heart Disease Patients by Tissue Doppler Imaging and its Relation with Functional Class

Ali Zahedmehr MD, Mansoor Mirzaali MD, Hamid Reza Sanati MD,
Reza Kiani MD, Anita Sadeghpour MD, Ata Firouzi MD, Majid Maleki MD

Abstract

Background- Left and right ventricular systolic and diastolic functions are contributors to the symptoms and prognosis in adults with congenital heart disease. Echocardiography is a simple tool to evaluate the ventricular function. Tissue Doppler imaging (TDI) may be a good complement in adult congenital heart disease given the altered geometry of the ventricles.

Methods- Forty-seven consecutive patients (29 male, mean age= 20 ± 3 years) presenting to the Adult Congenital Heart Disease clinic were evaluated by conventional echocardiography and TDI to assess the right and left ventricular systolic and diastolic functions and their relation with subjective functional class (FC).

Results- Six (12.8%) patients had left ventricular ejection fraction (LVEF) $<50\%$; eleven (23.4%) patients had moderate RV systolic dysfunction, and one (2.1%) patient had severe RV dysfunction. Those patients with at least FC II had a significantly lower LVEF ($P=0.001$) and RVEF ($P=0.007$) comparing with asymptomatic patients or those with FC I. By TDI, those who had RV Ea (early diastolic myocardial relaxation velocity) $<Aa$ had a significantly higher FC ($P=0.02$), and those who had LV Em <8 had a higher FC; this relation, however, was not significant.

Conclusion- Left and right ventricular dysfunctions have significant correlations with FC in adult congenital heart diseases. TDI may improve conventional echocardiography in the assessment of the ventricular function (*Iranian Heart Journal 2010; 11 (3):13-18*).

Key words: congenital heart disease ■ ventricular function ■ tissue Doppler imaging

With progressive improvements in the diagnosis and treatment of congenital heart disease (CHD) in pediatric cardiology, nowadays many of such patients reach adulthood. The estimated number of adults living with CHD is now greater than the estimated children with CHD.^{1,2} Systolic and diastolic left ventricular dysfunctions may be the cause of exercise intolerance and determine the time for interventions or redo surgeries in adult patients. The right ventricular dysfunction is also a key factor in morbidity and mortality and in the determination of the necessity of reoperation.^{3,4}

Conventional echocardiography is a routine examination to evaluate the ventricular function; however, given the altered ventricular geometry, especially in postoperative complex CHD, assessment of the right and left ventricular functions is difficult.^{5,6} Visual evaluation of the ventricular function by 2D echocardiography suffers from being subjective and provides only semiquantitative data. Furthermore, visual assessment has limited ability to detect more subtle changes in the function and changes in the timing of myocardial motion throughout systole and diastole.^{3,5} On the other hand, the mitral

inflow velocity (E) in Doppler studies has a bimodal distribution, which occurs due to preload compensation in the more severe stages.⁶

Tissue Doppler Imaging (TDI) has been introduced as a quantitative and more objective method to quantify ventricular systolic and diastolic functions.⁵ Systolic myocardial velocity (Sa) at the mitral annulus is a measure of the longitudinal systolic function, which correlates with left ventricular ejection fraction.^{7,8} Ea, which is early diastolic myocardial relaxation velocity, has a unimodal distribution and shows a steady decline with increasing diastolic dysfunction.^{5,9}

TDI has also shown its efficacy in the evaluation of the right ventricular function in CHD.^{3,5,10}

With this background, we decided to assess both ventricles in adult CHD patients by conventional echocardiography and TDI and confirm the results by finding correlations with the patients' functional classes.

Methods

This was a case-series, descriptive, and analytic study. ACHD patients who were referred to our clinic underwent transthoracic (or if needed, transesophageal) echocardiography to determine residual lesions and

ventricular systolic and diastolic functions. Simpson, visual evaluation, total annular plane systolic excursion (TAPSE), and TDI were used. The application of tricuspid annular plane systolic excursion (TAPSE) as an additional echocardiographic tool to analyze the right ventricular systolic function has been established as a simple, repeatable, and highly reproducible method.^{11,17} In adults, it has been shown that TAPSE < 2 cm indicates a right ventricular ejection fraction of < 40%.¹⁸ Functional class was determined subjectively from history.

The echocardiographic studies were performed with a Vivid 3 digital ultrasound system (GE Vingmed Ultrasound, Horten Norway) with a M3S transducer.

Left ventricular volume and ejection fraction (EF) were evaluated by visual assessment and Simpson's method and left ventricular dysfunction was graded as mild (EF < 50%), moderate (< 40%), and severe (< 30%).³ By TDI, LV-Sa < 6 cm/sec was considered abnormal systolic function. The left ventricular diastolic dysfunction was defined by Ea < 8 cm/sec in TDI. The right ventricular systolic and diastolic functions were assessed by the total annular plane systolic excursion (TAPSE) in M mode and TDI.

For TDI assessment, the tricuspid annular velocity at the junction of the tricuspid annulus and the right ventricular lateral wall was recorded from the apical four-chamber view. TDI of the mitral annulus was also measured in the apical four-chamber view.

The right ventricular systolic dysfunction was defined by S velocity < 11 cm/sec. The right ventricular diastolic dysfunction was defined by Ea < Aa.

After determining the frequencies of the left ventricular and right ventricular systolic and diastolic functions, we analyzed the correlation between these parameters and subjective functional class by the χ^2 and Anova methods.

Results

The total number of our patients was 47, comprised of 29 (61.7%) men and 18 (38.3%) women with a mean age of 20 ± 3 years.

About 24 (51.1%) patients had simple CHD (e.g. ASD, VSD, PS, etc.), and the remaining 23 (48.9%) had complex anomalies (e.g. TF, AVSD, etc.).

In the simple group, 11 (45.8%) patients had a history of corrective surgery and 13 (54.2%) patients were non-corrected. In the complex group, 16 (69.6%) had corrective and 4 (17.4%) had palliative surgeries and 3 (13%) patients had not undergone surgery.

In the simple group, 15 (62.5%) patients were asymptomatic, 7 (29.2%) had dyspnea on exertion FC I, and 2 (8.3%) were in FC II. In the complex patients, 15 (65.2%) were asymptomatic, 3 (13%) in FC I, and 5 (21.7%) in FC II.

The range of LVEF was between 40 to 65%. Totally, 41 (87.2%) patients had LVEF $\geq 50\%$ and 6 (12.8%) had LVEF < 50%.

According to TDI, 40 (85%) patients had LV-Sa ≥ 6 , and 7 (15%) had LV systolic dysfunction (LV-Sa < 6). The correlation coefficient between LVEF and LV-Sa was 0.09 (P=0.57).

By TDI, left ventricular diastolic function was normal (Ea ≥ 8) in 42 (89%) patients and abnormal (Ea < 8) in 5 (11%).

The results of RVEF assessment visually and by TAPSE are shown in Table I.

Table I. Functional capacity in the simple and complex groups

	Asymptomatic	FC I	FC II
Simple	62.5% (15)	29.2% (7)	8.3% (2)
Complex	65.2% (15)	13% (3)	21.7% (5)

According to TDI, 27 (57.4%) patients had RV-Sa ≥ 11 and 20 (42.6%) had RV dysfunction and RV-Sa < 11. Correlation coefficient between RVEF and RV-Sa was 0.53, which was significant (P<0.0001, Fig. 1).

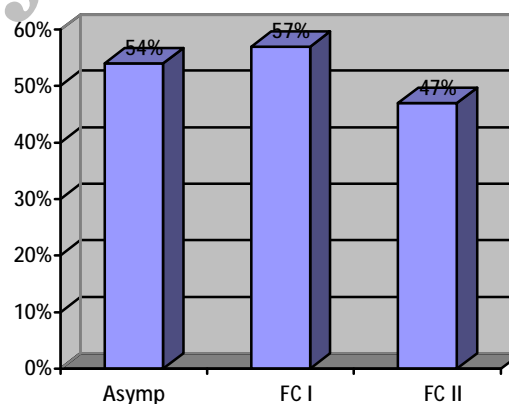


Fig. 1. Mean LVEF in different functional classes

By TDI, the right ventricular diastolic function was normal (Ea > Aa) in 33 (70%) patients and abnormal (Ea < Aa) in 14 (30%). Those patients with a higher functional class (FC II) had significantly lower LVEF than the asymptomatic or FC I patients (P=0.001). The patients with an abnormal left ventricular systolic function by TDI (Sa < 6) had a higher functional class. Similarly, those who had an abnormal left ventricular diastolic function by TDI (LV Ea < 8) had a higher functional class, but these relations were not significant.

On the other hand, those patients with a higher functional class (FC II) had a significantly lower RVEF than the asymptomatic or FC I patients (P<0.001). The

patients with an abnormal right ventricular systolic function by TDI ($Sa < 11$) had a higher functional class, but this relation was not significant.

Those who had an abnormal right ventricular diastolic function by TDI ($Ea < Aa$) had a significantly higher functional class ($P=0.02$).

Discussion

Congenital heart diseases are now an important problem in adult cardiology. We will see more and more complex cases reaching adulthood and expecting an ordinary and asymptomatic life.

Right or left ventricular dysfunction may be important contributors to exercise intolerance.

In this study, the patients in the simple group were mostly asymptomatic, in contrast to the complex group, who were more commonly symptomatic.

All our patients had LVEF/40%, and half of them had a normal RVEF.

By TDI, we observed almost the same percentages as above for the left ventricular and right ventricular systolic functions, but those patients with abnormal TDI were not necessarily those with LVEF $< 50\%$ or reduced RVEF. It, therefore, seems that some patients with a normal or preserved EF may show important abnormalities in TDI.

We noticed that the left ventricular systolic dysfunction and right ventricular systolic and diastolic dysfunctions had a significant correlation with a higher functional class. There was also a trend between the left ventricular diastolic dysfunction and a higher functional class.

Our data are consistent with those of Puranik et al., who suggested that the systolic and early diastolic right ventricular basal wall TDI velocities were frequently abnormal in asymptomatic operated tetralogy of Fallot and transposition of great arteries patients, even though the right ventricular function otherwise appeared normal, suggesting subclinical abnormalities of the right ventricular performance.^{19,20}

It should be noted that asymptomatic patients with mild ventricular dysfunction by echocardiographic evaluation have an increased risk of congestive heart failure and death.²¹

Some previous studies have shown that TDI detects ventricular dysfunction prior to alterations in conventional echocardiographic indices.²¹

It is yet unclear whether finding early subtle cardiac dysfunction by TDI means susceptibility to future morbidity and mortality.²¹ Some recent studies have shown that the left ventricular dysfunction (systolic and diastolic) measured by TDI may be a powerful and independent predictor of death in the general population.²²

So finally, it seems reasonable to pay more attention to TDI abnormalities, although in some situations they may not be enough to warrant re-intervention.

Conclusion

Left and right ventricular dysfunctions have significant correlations with the functional class in ACHD. TDI improves the diagnostic strength of conventional echocardiography in the assessment of the ventricular function and detecting subclinical abnormalities of the ventricular function.

Conflict of interests

None has been claimed by the authors.

Table II. LV ejection fraction in the simple and complex groups

	LVEF $\geq 50\%$	LVEF $< 50\%$
Simple	95.9% (23)	4.1% (1)
Complex	78.3% (18)	21.7% (5)

Table III. RV systolic function (P value = 0.03)

RVEF	Normal	Mildly reduced	Moderately reduced	Severely reduced
Simple	17 (70.8%)	5 (20.8%)	2 (8.3%)	0 (0%)
Complex	8 (34.8%)	5 (21.7%)	9 (39.1%)	1 (4.3%)

Table IV. Relation between RV diastolic TDI and functional class (P value = 0.02)

RV diastolic TDI	Ea \geq Aa	Ea $<$ Aa
Asymptomatic	93.3% (28)	6.7% (2)
FC I	60% (6)	40% (4)
FC II	29% (2)	71% (5)

Table V. Relation between LV diastolic TDI and functional class

LV diastolic TDI	Em ≥ 8	Em < 8
Asymptomatic	30 (100%)	0 (0%)
FC I	7 (70%)	3 (30%)
FC II	5 (71%)	2 (29%)

Table VI. Relation between RVEF and functional class (P < 0.001)

RVEF	Normal	Mild dysfx.	Moderate dysfx.	Severe dysfx.
Asymptomatic	16 (53%)	9 (30%)	5 (17%)	0 (0%)
FC I	7 (70%)	1 (10%)	2 (20%)	0 (0%)
FC II	2 (29%)	0 (0%)	4 (57%)	1 (9%)

Table VII. Relation between LV systolic TDI and functional class

LV systolic TDI	Sm ≥ 6	Sm < 6
Asymptomatic	30 (100%)	0 (0%)
FC I	7 (70%)	3 (30%)
FC II	3 (43%)	4 (57%)

Table VIII. Relation between RV systolic TDI and functional class

RV systolic TDI	Sa ≥ 11	Sa < 11
Asymptomatic	20 (67%)	10 (33%)
FC I	5 (50%)	5 (50%)
FC II	2 (29%)	5 (71%)

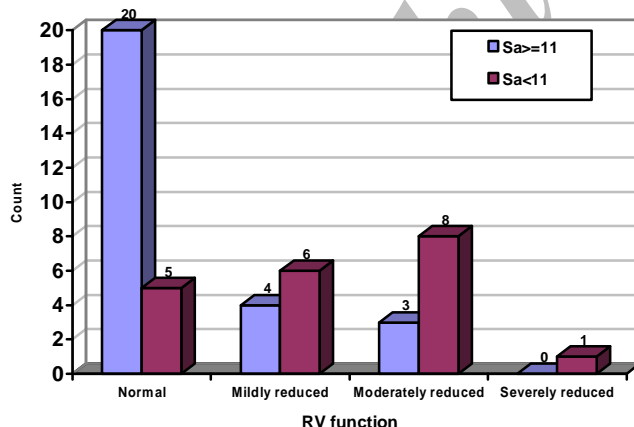


Fig. 2. Comparing right ventricular function by conventional method and TDI

Conflict of Interest

No conflicts of interest have been claimed by the authors.

References

- Williams RG, Pearson GD, Barst RJ, Child JS, del Nido P, Gersony WM et al. Report of the National Heart, Lung and Blood Institute Working Group on Research in Adult Congenital Heart Disease. *J Am Coll Cardiol* 2006; 47: 701-707.
- Marelli A, Mackie A, Ionescu-Ittu R, Marelli AJ, Mackie A S, and Pilote L. Congenital heart disease in the general population: Changing prevalence and age distribution. *Circulation* 2007; 115: 163-172.
- Kadar K. Tissue Doppler imaging in the assessment of right ventricular function in congenital heart disease. Correlation with echo - MRI. *Orv Hetil* 2008, Aug 10; 149 (32): 1503-8.
- Noori NM, Mehralizadeh S, Khaje A. Assessment of right ventricular function in children with congenital heart disease by tissue Doppler imaging. *Saudi Medical Journal* 2008 Vol. 29 (8): 1168-72.
- Otto CM. The Practice of Clinical Echocardiography. Third edition, 2007, W. B. Saunders - Elsevier.
- Price DJ, Wallbridge DR, Stewart MJ. Tissue Doppler imaging: current and potential clinical applications. *Heart* 2008; 84 (suppl II): ii 11-ii 18.
- Galiuto L, Ignone G, Demaria AN. Contraction and relaxation velocities of the normal LV using pulse-wave tissue Doppler echocardiography. *Am J Cardiol* 1998, 81: 609-14.
- Ho CY, Solomon SD. A clinician's guide to tissue Doppler imaging. *Circulation* 2006, 113: e 396-8.
- Zehetgruber MG. Tissue Doppler imaging: myocardial velocities and strain - are there clinical applications? *Journal of Clinical and Basic Cardiology* 2002; 5 (Issue z), 125-32.
- Gentles TL. Watching the right ventricle in treated congenital heart disease. *Heart* 2007; 93: 1502-3.
- Gupta S, Khan F, Shapiro M, Weeks SG, Litwin SE, Michaels AD. The associations

- between tricuspid annular plane systolic excursion (TAPSE), ventricular dyssynchrony, and ventricular interaction in heart failure patients. *Eur J Echocardiogr* 2008; 9: 766–771.
12. Dini FL, Conti U, Fontanive P, Andreini D, Banti S, Braccini L, et al. Right ventricular dysfunction is a major predictor of outcome in patients with moderate to severe mitral regurgitation and left ventricular dysfunction. *Am Heart J* 2007; 154: 172–179.
 13. Ghio S, Recusani F, Klersy C, Sebastiani R, Laudisa ML, Campana C, et al. Prognostic usefulness of the tricuspid annular plane systolic excursion in patients with congestive heart failure secondary to idiopathic or ischemic dilated cardiomyopathy. *Am J Cardiol*. 2000; 85: 837–842.
 14. Lamia B, Teboul JL, Monnet X, Richard C, Chemla D. Relationship between the tricuspid annular plane systolic excursion and right and left ventricular function in critically ill patients. *Intensive Care Med*. 2007; 33: 2143–2149.
 15. Lang RM, Bierig M, Devereux RB, Flachskampf FA, Foster E, Pelikka PA, et al. Recommendations for chamber quantifications: a report from the American Society of Echocardiography's Guidelines and Standards Committee and the Chamber Quantification Writing Group, developed in conjunction with the European Association of Echocardiography, a branch of the European Society of Cardiology. *J Am Soc Echocardiogr* 2005; 18: 1440–1463.
 16. Miller D, Farah MG, Liner A, Fox K, Schluchter M, Hoit BD. The relation between quantitative right ventricular ejection fraction and indices of tricuspid annular motion and myocardial performance. *J Am Soc Echocardiogr* 2004; 17: 443–447.
 17. Kaul S, Tei C, Hopkins JM, Shah PM. Assessment of right ventricular function using two-dimensional echocardiography. *Am Heart J* 1984; 107: 526–531.
 18. Lee CY, Chang SM, Hsiao SH, Tseng JC, Lin SK, Liu CP. Right heart function and scleroderma: insights from tricuspid annular plane systolic excursion. *Echocardiography*. 2007; 24: 118–125.
 19. Perloff JK, Child JS, Aboulhosn J. *Congenital Heart Disease in Adults*. Third edition, 2009, Saunders - Elsevier.
 20. Puranik R, Greaves K, Hawker RE. Abnormal right ventricular tissue velocities after repair of congenital heart disease, implications for late outcomes. *Heart Lung Circ* 2007; 16: 295–299.
 21. Neilan TG, Jassal DS, Perez-Sanz TM, Raher MJ, Pradhan AD, Buys ES, et al. Tissue Doppler imaging predicts left ventricular dysfunction and mortality in a murine model of cardiac injury. *European Heart Journal* 2006, 27 (15): 1868–75.
 22. Mogelvang R, Sogaard P, Pedersen SA, Olsen NT, Marott JL, Schnohr P, et al. Cardiac dysfunction assessed by echocardiographic tissue Doppler imaging is an independent predictor of mortality in the general population. *Circulation* 2009; 119: 2679–85.