

Pseudoaneurysm of Ascending Aorta with Fistulization to Left Atrium after Coronary Artery Bypass Graft Surgery

Maryam Shojaeifard, MD; Majid Maleki, MD. FACC; Saeid Hosseini, MD

Abstract

A 53-year-old man with a history of coronary artery bypass graft surgery 4 years previously was admitted to our hospital with dyspnea on exertion (New York Heart Association class II)¹ of three months' duration, lower extremities edema of two weeks' duration, and pulmonary edema of two weeks' duration. Transthoracic and transesophageal echocardiographic examinations revealed pseudoaneurysm of the ascending aorta with fistulization to the left atrium. He was, therefore, scheduled for surgery, during which repair of the ascending aorta with a pericardial patch in conjunction with repair of the aortic valve and removal of the fistulization between the left atrium and ascending aorta was performed. The patient was discharged ten days after admission in very good physical condition. Postoperative echocardiography demonstrated only mild aortic regurgitation and no residual connection between the left atrium and ascending aorta, with the latter having a normal size (*Iranian Heart Journal 2011; 12 (3):57-59*).

Keywords: Pseudoaneurysm of ascending aorta ■ Fistulization to LA ■ CABG

Pseudoaneurysms of the ascending aorta occur in less than 0.5% of cardiac surgical patients.¹ After coronary artery bypass grafting (CABG), the site of aortic cannulation is most commonly involved, followed by the anastomotic suture line. Pseudoaneurysms of the ascending aorta are considered an urgent or emergent surgical priority and carry high operative morbidity and mortality. We herein report a case of the pseudoaneurysm of the ascending aorta with fistulization to the left atrium (LA), which had developed late after CABG.

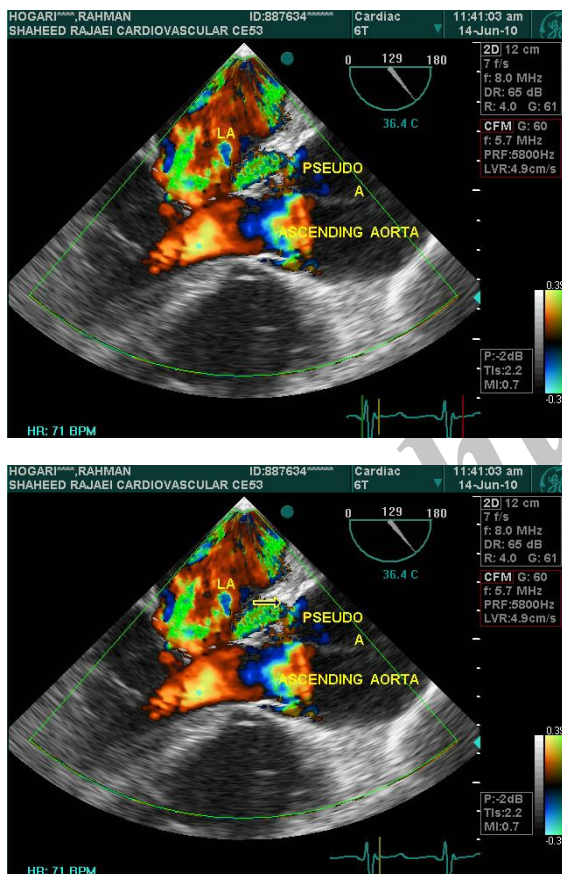
Case Report

A 53-year-old man with a history of CABG four years previously (left internal mammary artery to left anterior descending, saphenous vein graft to obtuse marginal, first diagonal, right coronary artery, and posterior descending artery) was admitted to our hospital with dyspnea on exertion New York Heart Association (NYHA) class II of a three

months' duration, lower extremities edema of two weeks' duration, and flash pulmonary edema as well as oliguria of approximately two weeks' duration. The patient's other signs were non-productive nocturnal coughs, orthopnea, and ascites. He also had a history of hypertension and was hemodynamically stable at admission. Physical examination revealed S4 gallop with systolic-diastolic murmur (continuous murmur) with III/VI severity in the apical, right, and left intercostal regions. Abdominal examination showed flank bulging due to ascites and peripheral edema with 4+ grading with extension to the scrotal region.

Laboratory data at admission showed anemia (HGB=11.2 mg/dl) with normal white blood cell and platelet counts and also mild azotemia with creatinine 1.8 mg/dl. Echocardiographic examination revealed a normal size left ventricle (LV), moderate systolic dysfunction (ejection fraction=40%), mild to moderate right ventricle (RV)

enlargement, and severe dysfunction with an echogenic semi-mobile mass in the RV apex adjacent to the moderator band; the mass was entrapped in the RV trabeculations and was suggestive of an organized clot. There was also aneurysmal dilation of the ascending aorta (5.7 cm) due to dissection and pseudoaneurysm formation at the posterior aspect of the ascending aorta (Fig. 1) with fistulization to the LA (Fig. 2), resulting in a continuous flow between the ascending aorta and the LA with a systolic pressure gradient of 35 mmHg and diastolic pressure gradient of 15 mmHg (Fig. 3).



The motion of the posterior mitral valve leaflet was restricted, giving rise to posterolaterally directed mitral regurgitation. The aortic valve was tricuspid with mild to moderate aortic insufficiency begotten by right coronary cusp prolapse. There was mild to moderate tricuspid regurgitation with moderate to severe pulmonary artery

hypertension (pulmonary artery pressure=60 mmHg). Coronary and aortic CT angiographic examinations showed patent grafts with aneurysmal dilation and out-pouching of the aortic root in consequence of pseudoaneurysm formation. The patient was transferred to the operating room, where it was observed that the ascending aorta was aneurysmal with a dissecting flap and was fistulated to the LA by a large pseudoaneurysm at the site of the saphenous vein graft to the right coronary artery. Repair of the aortic valve, supra commissural tube graft insertion of the ascending aorta, and repair of the LA were performed surgically.

Intraoperative transesophageal echocardiography revealed mild aortic regurgitation with normal functioning of the tube graft of the ascending aorta. On the 5th postoperative day, repeat transesophageal echocardiography showed normal LV size with severe systolic and grade II diastolic dysfunction and mild enlargement of the RV with severe systolic dysfunction. There were also mild aortic regurgitation with no aortic stenosis and hematoma around the ascending aorta about 8 mm in size; there was, however, no fistula to the aorta or any chamber and nor was there any flow or connection to the LA or the left ventricular outflow tract. The patient was discharged in good physical condition without any complications.

Discussion

Pseudoaneurysms of the ascending aorta result from a tear or perforation in the aortic wall and from leakage of blood from the aorta into a contained aneurysmal cavity. Pseudoaneurysms are referred to as false aneurysms.¹ Pseudoaneurysms are caused by a defect in the two inner layers (intima and media) with the continuity of the outer layer (adventitia). Alternatively, all the three layers are damaged and the bleeding is contained by a blood clot or the surrounding structures.¹ Ascending aortic pseudoaneurysms are a rare

complication of cardiac surgery and most frequently occur at the site of graft anastomosis, aortotomy, or cannulation.¹ The incidence of pseudoaneurysms arising from the vascular graft-to-aorta anastomoses or coronary ostial anastomoses is very low and is reported to range from 0 to 6%.^{2,3,4} In our patient, there was a pseudoaneurysm of the ascending aorta originating from the posterior aspect of the ascending aorta at the site of the saphenous vein graft anastomosis to the right coronary artery and fistulating to the LA at the site of aortic cannulation. The patient underwent surgery, during which it was observed that the ascending aorta was dissected, creating a pseudoaneurysm fistulating to the LA at the site of the saphenous vein graft. The aortic valve was repaired and the ascending aorta was exchanged with an ascending tube graft number 28 in a supra commissural surgical procedure. Intraoperative transesophageal echocardiography confirmed the success of the operation.

Conclusion

Pseudoaneurysms of the ascending aorta are an infrequent complication of cardiac surgery and most frequently occur at the site of graft anastomosis, aortotomy, or cannulation. In our patient, the pseudoaneurysm was created at the site of the graft anastomosis, and the erosion into the LA and fistula formation was probably caused by continuous pulsatile friction between the pseudo-aneurysmatic wall and the LA or at the aortic cannulation site. This phenomenon had triggered symptoms of high cardiac output failure and a more recent flash pulmonary edema. Our physical examination revealed continuous murmur, which has a differential diagnosis with the ruptured Valsalva sinus or coronary artery fistula. Be that as it may, an exact echocardiographic examination should

comprise Computed Tomography, Cardiac Magnetic Aortography, right heart catheterization, and Magnetic Resonance Angiography for accurate differentiation and confirmation of the diagnosis of the pseudoaneurysm of the ascending aorta with fistulization to the LA.⁵ Surgical management is always mandatory because of lethal complications. Our patient was successfully managed using a median sternotomy associated with femoro-femoral bypass and deep hypothermic circulatory arrest, as has already been reported by others in the literature.

References

1. Mojca Konia, MD, Jeffrey Uppington, MD, Peter Moore, MD, PhD and Hong Liu, MD Ascending Aortic Pseudoaneurysm: A Late Complication of Coronary Artery Bypass. *Anesthesia and Analgesia* 2007 oct.
2. Radim Brat, Tomas Danek, Vaclav Maly. Combination of two pseudoaneurysms in a patient 6 years after ascending aorta and aortic valve replacement *Biomed Pap Med Fac Univ Palacky Olomouc Czech Repub.* 2007, 151(1):125–127.
3. Milano AD, Pratali S, Mecozzi G, Boraschi P, Braccini G, Magagnini E, Bortolotti U. Fate of coronary ostial anastomoses after the modified Bentall procedure. *Ann thorac Surg* 2003 Jun;75(6):1797–801.
4. Schachner T, Vertacnik K, Nagiller J. Factors associated with mortality and long time survival in patients undergoing modified Bentall operations. *J Cardiovasc Surg (Torino)* 2005 Oct; 46(5): 449–55.
5. A. Bol, L. Missault, K. M. Dossche, J. Delanote Aortopulmonary Artery Fistula in Atherosclerotic Pseudoaneurysm Presenting with Congestive Heart Failure after Aortic Valve Replacement, *Acta chir belg*, 2006, 106, 240-242.