

Hydatid Cyst of Heart and Mediastinum: Report of Three Cases

M. Mirmohammad Sadeghi MD, A. A. Tavassoli MD, M. Hashemi MD,
Z. Massaeli MD and M. R. Jaberi MD

Abstract

We describe three cases of hydatid cyst of the heart. The first patient was a 46-year-old man who was found to have a systolic murmur on routine physical examination and echocardiography showed an interventricular cyst. He was operated on and recovered uneventfully.

The second patient was a 55-year-old woman with a hydatid cyst of the interventricular septum, which was diagnosed by echocardiography. The cyst was resected surgically. She developed complete heart block after surgery, which was managed by an epicardial pacemaker.

The third patient was a 15-year-old girl who was diagnosed with a large hydatid cyst of the left ventricle by echocardiography, but during the operation in addition to the left ventricular cyst a mediastinal cyst was found in the left side of the inferior vena cava. Both cysts were resected surgically and the patient recovered without any complication (*Iranian Heart Journal* 2006; 7 (3):52-55).

Key words: cardiac hydatid cyst ■ cardiac cyst ■ cardiac echinococcosis

Echinococcosis is an infection caused in humans by the larval stage of *Echinococcus granulosus*, *E. multilocularis*, or *E. vogeli*.¹ It has two forms: hydatid or unilocular cyst disease, caused by *Echinococcus granulosus* or *E. vogeli*, and alveolar cyst disease caused by *Echinococcus multilocularis*.² *E. granulosus* is prevalent in areas where livestock is raised in association with dogs.¹ This tapeworm species is found in Australia, Argentina, Chile, Africa, Eastern Europe, the Middle East, New Zealand, and the Mediterranean region.¹

The hydatid cysts of *Echinococcus granulosus* tend to form in the liver (50% to 70% of patients) or lung (20% to 30%) but may be found in any organ of the body, including brain, heart, and bones (less than 10%).²

Hydatid cysts contain a germinal layer that allows asexual budding to form daughter cysts within the primary cyst (Fig. 1).

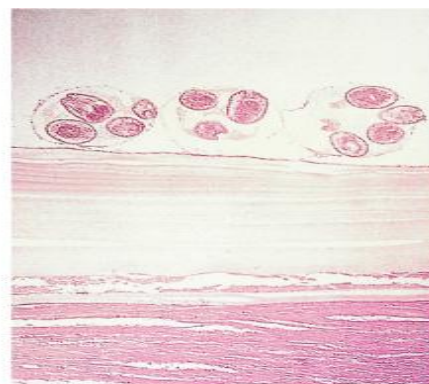


Fig. 1: Daughter cyst formation from the germinal membrane of a hydatid cyst. (From Ash LR, Orihel TC. *Atlas of Human Parasitology*. 3rd ed. Chicago: ASCP; 1990).¹⁴

Received June 13, 2005; Accepted for publication Sep. 26, 2006.

From the, Department of Cardiac Surgery, Chamran Heart Center, Isfahan, Iran. Shareef Waquefi Street, Block 710, Isfahan, Iran.

Tel: 03112653743 – 03112214409

Fax: 03112607075

E-mail: zmassaeli@yahoo.com

If a cyst erodes into the biliary tree or a bronchus, the cyst contents, including daughter cysts, may enter the lumen and cause obstruction or post-obstructive bacterial infection.²

Cardiac involvement in hydatid disease is rare, occurring in less than 2% of cases of hydatid infections. It can occur as part of a widespread systemic infection or as an isolated event.³ In cardiac involvement the cysts are usually in the interventricular septum or left ventricular free wall, but the involvement of the right ventricle or atrium may also occur. In most cases, a single cardiac cyst is present.⁴

The cardiac symptoms and signs depend on the location, size and integrity of the cyst. Occasionally, cardiac murmur may be heard due to right ventricular outflow obstruction or mitral valve apparatus dysfunction or other mechanisms.⁴ Infection that is suspected based on imaging studies (ultrasonography, CT, MRI) may be confirmed by a specific enzyme-linked immunosorbant assay (ELISA) and Western blot serology confirming exposure to the parasite.²

Imaging plays an important role in the diagnosis. Hydatid cysts of the heart are diagnosed mostly by echocardiography and confirmed by computed tomography and/or magnetic resonance imaging according to the cases reported in different articles.⁵⁻¹²

Current treatment involves attempted surgical resection with long-term follow-up chemotherapy (albendazole).^{1,3}

Case Reports

In Chamran Hospital, where 700 open heart procedures are done annually, three cases of hydatid cyst of the heart have been diagnosed and treated over the past 10 years.

Patient 1 A 46-year-old man was admitted to our hospital for the management of a cystic mass in his heart. He was found to have a systolic murmur on routine physical examination, for which echocardiography was

done and a cystic mass was found in the interventricular septum obstructing the right ventricular outflow tract (Fig. 2). This mass was suggestive of hydatid cyst.

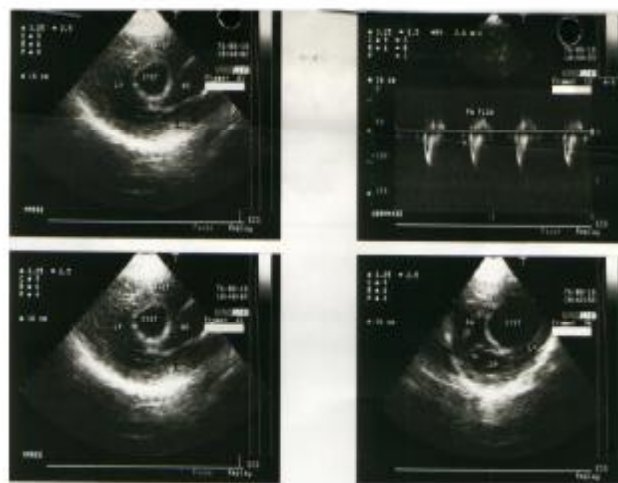


Fig. 2: Echocardiography of the first patient showing hydatid cyst in interventricular septum.

Diagnostic angiography showed a round mass in right ventricular outflow tract, which was fluid-filled. Surgical resection of the mass was recommended.

The patient was approached surgically with median sternotomy. A large cystic mass was found in the interventricular septum, which was bulging to the right ventricular free wall. Right ventricle was opened vertically, cystic fluid was aspirated and hypertonic saline was injected into the cyst. The cyst was opened after 5 minutes and evacuated completely. The interventricular septal defect was repaired with a Dacron patch. Right ventricle was closed with a pericardial patch. The patient recovered uneventfully and was discharged after 7 days.

Patient 2 A 55-year-old woman was admitted with symptoms of shortness of breath and palpitation without apparent arrhythmia. Physical examination was unremarkable. Chest X-ray was normal. Echocardiography showed a cystic mass in the interventricular

septum, suggestive of a hydatid cyst. The cyst was removed surgically (Figs. 3, 4). The patient developed complete heart block after surgery, which was managed by an epicardial pacemaker.

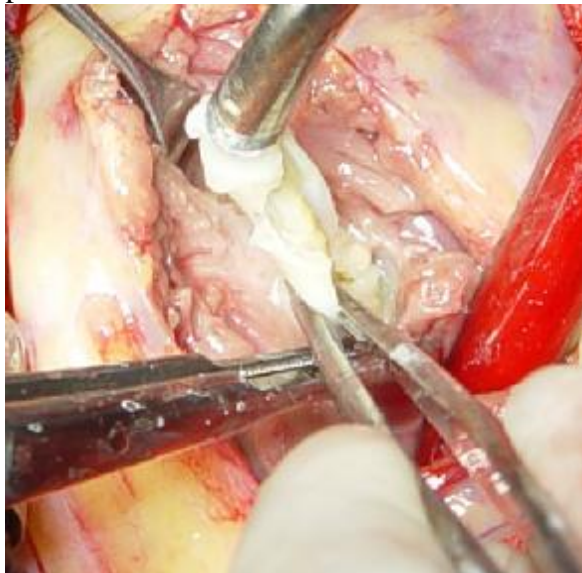

Fig. 3. View of open heart surgery of the second patient.

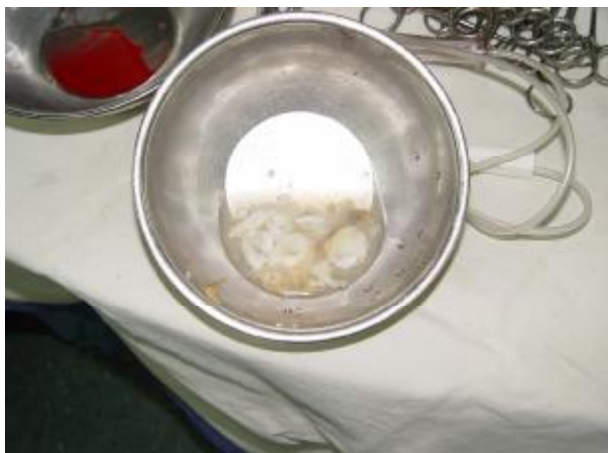

Fig. 4. Hydatid cysts removed from the second patient.

Patient 3 A 15-year-old girl was admitted to our hospital complaining of palpitation and easy fatigability upon effort for the past year. Her symptoms were exacerbated after a running race. Physical examination revealed an apical pansystolic murmur. Echocardiography showed a large cyst (48 x 29 mm) in the free wall of the left ventricle posteriorly, in the left ventricular cavity.

The patient was operated on via median sternotomy. Severe adhesion was noted between the heart and the pericardium, which was released by sharp and blunt dissection. A large cyst was seen in the left side of the inferior vena cava and below the left pulmonary veins (which was not diagnosed by echocardiography). This mediastinal cyst was excised by sharp dissection. Then 20% sodium chloride was injected into the cyst of the left ventricle, which was located in the posterior aspect of the ventricle. After 10 minutes, it was opened and the daughter cyst was removed intact. Posterior left ventricular wall was repaired by 3-0 prolene suture. The patient recovered without any complications and was discharged 8 days after operation.

Discussion

Cardiac involvement in hydatid disease may be asymptomatic for a long period before presenting with a myriad of non-specific symptoms. Imaging plays an important role in the diagnosis.³ Although two-dimensional echocardiography is the best diagnostic tool for cardiac involvement,¹³ we recommend thoracic CT scanning or magnetic resonance imaging (MRI) for all cases of cardiac hydatidosis in order to exclude multiple cysts, as in the second case presented in this article.

References

1. Clinton White A., Weller F. Cestodes. In: Braunwald E, Fauci AS, Kasper DL, Hauser SL, Longo DL, Jameson JL, (eds.) *Harrison's Principles of Internal Medicine*. New York: McGraw-Hill, 2005, pp. 1272-77.
2. King CH. Cestodes (Tapeworm). In: Mandell GL, Bennett JE., Dolin R. (eds.) *Principles and Practice of Infectious Diseases*. USA, Elsevier Churchill-Livingstone, 2005, pp. 3285-93.
3. Snodgrass D, Blome S. Cardiac hydatid disease: report of two cases. *Austral Radiol* 2002 Jun; 46(2): 194-6.

4. Braunwald E. Heart Disease. 6th ed. Philadelphia, W. B. Saunders Co., 2001, pp. 1792.
5. Cacoub P, Chapoutot L, Du-Boutin LT, Derbel A, Gandjbakhch I, Sal R, Godeau P. Hydatid cyst of the interventricular septum. Contribution of magnetic resonance imaging. Arch Mal Coeur Vaiss 1991; Dec. 84 (12): 1857-60.
6. Emirogullari N, Uzum K, Ustunbas HB, Andac H, Tasdemir K. Primary cardiac echinococcosis in childhood. Case report. Scand J Thorac Cardiovasc Surg 1995; 29 (3): 153-6.
7. Kabbaj N, Chat L, Dafiri R, Imani F. Rare cause of ischemic cerebrovascular infarct in a young patient: cardiac hydatid cyst. J Radiol 1998 Jan; 79 (1): 53-6.
8. Kammoun S, Frikha I, Fourati K, Fendri S, Benyoussef S, Sahnoun Y, Daoud M, Dumesnil JG. Hydatid cyst of the heart located in the interventricular septum. Can J Cardiol 2000 Jul; 16(7): 921-4.
9. Kanadasi M, Demirtas M, San M, Ozer C, Soyupak SK, Kisacikoglu B. Mobile right atrial hydatid cyst with multiorgan involvement. Catheter Cardiovasc Interv 2000 Feb; 49 (2): 204-7.
10. Keles C, Sismanoglu M, Bozbuga N, Erdogan HB, Akinci E, Ipek G, Yakut C. A cardiac hydatid cyst involving the basal interventricular septum causing biventricular outflow tract obstruction. Thorac Cardiovasc Surg 2000 Dec; 48(6): 377-9.
11. Papagna D, Aloe MA, Spagnolo S. Cardiopulmonary echinococcosis: a report of a clinical case. G Ital Cardiol 1991 Oct; 21(10): 1129-33.
12. Pasaoglu I, Dogan R, Pasaoglu E, Tokgozoglu L. Surgical treatment of giant hydatid cyst of the left ventricle and diagnostic value of magnetic
13. Salih OK, Celik SK, Topcuoglu MS, et al. Surgical treatment of hydatid cyst of the heart: A report of 3 cases and a review of the literature. Can J Surg 1998; 41:321.