

Repair of Interrupted Aortic Arch Type B by Left Thoracotomy Approach

Gholamreza Omrani MD, Ramin Baqaii Tehrani MD and Bahador Baharestani MD

Abstract

Interrupted aortic arch is a complete luminal and anatomical discontinuity between two segments of the aortic arch. According to the site of interruption there are three types of this anomaly.

As the nature of this anomaly is life threatening and that the complex corrective operation utilizing CPB and/or total circulatory arrest is associated with significant morbidity and mortality, we present a technique of off-pump repair of interrupted aortic arch via left thoracotomy approach (*Iranian Heart Journal 2006; 7 (3):56-58*).

Key words: interrupted aortic arch ■ thoracotomy

Interrupted aortic arch is complete luminal and anatomic discontinuity between two segments of the aortic arch. The aortic arch may be interrupted at one of three sites. It may be interrupted just distal to the left subclavian artery (type A of Celioia and Patton)³ with blood flowing into the descending aorta from the ductus arteriosus. About 40% of cases are type A. The most common site of interruption (55%) is proximal to the left subclavian artery between it and the left common carotid artery (type B). Characteristically, the ascending aorta is about half the normal diameter and is straight, dividing into two branches of about equal size (the V sign) and the pulmonary trunk is huge. The descending aorta is a direct continuation of the ductus arteriosus, as in the fetus, and is usually slightly larger than the ascending aorta (Fig. 1).

A large VSD is nearly always present, and frequently the outlet (conal) septum is malaligned and displaced posteriorly and leftward.

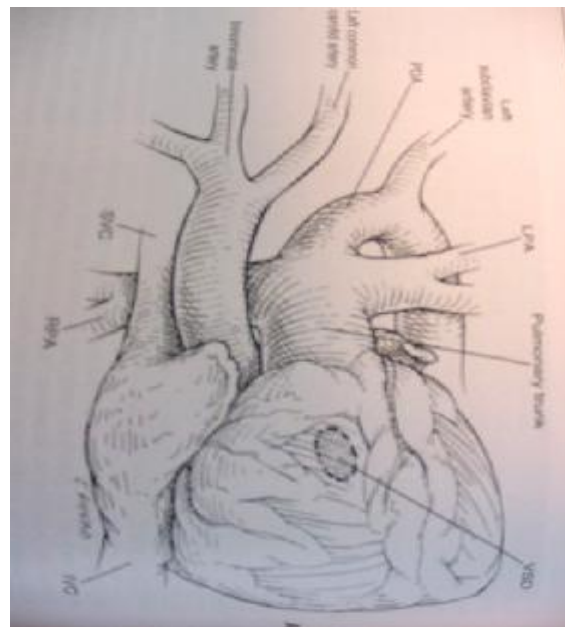


Fig. 1. Schematic view of interrupted aortic arch type 2

Interrupted aortic arch comprised 1% to 4% of autopsy cases of congenital heart disease and 1.3% of infants presenting with critical congenital heart disease.

This uncommon anomaly is highly lethal because the median age of death is 4 to 10 days, and 75% of such babies are dead within 1 month of birth.

Technique of operation

One-stage repair is considered optimal by some centers, but others indicate that few advantages are gained using this technique when compared with staged repair, in which the arch is repaired via left thoracotomy approach and the VSD is managed by either a concomitant pulmonary trunk banding or by subsequent intracardiac closure at a separate operation.¹

In general, coexisting cardiac anomalies are repaired concomitantly except for those in which a Fontan or other complex operations is required for coexisting cardiac anomalies; otherwise, almost all patients present as critically ill neonates in severe heart failure as a result of the combined effects of volume overload (from left to right intracardiac shunting) and high afterload imposed by the closing ductus. In the presence of total aortic interruption, metabolic acidosis and anuria develop rapidly.

Hypothermia and circulatory arrest in such ill patients have their own risk. We operated on two sick infants with interrupted aortic arch type B who needed complex surgery for coexisting cardiac anomalies with left thoracotomy approach without CPB and TCA (Fig. 2.).

Proximal partial clamping of the innominate artery with total clamping of the left common carotid artery gave good protection via the right common carotid artery, right subclavian and right vertebral artery from Willis circulation. In rare cases of the absence of the anterior or posterior communicating artery, it provides good brain protection too.

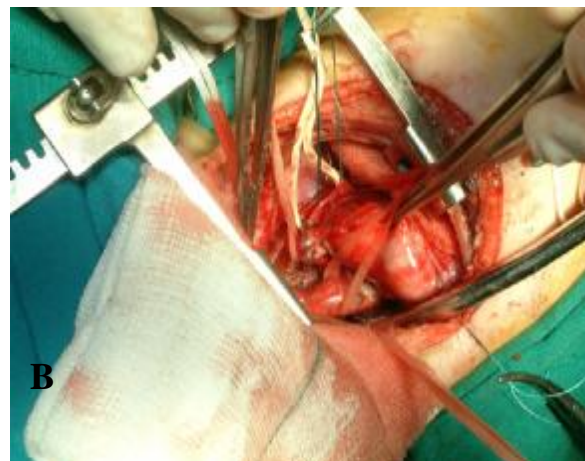
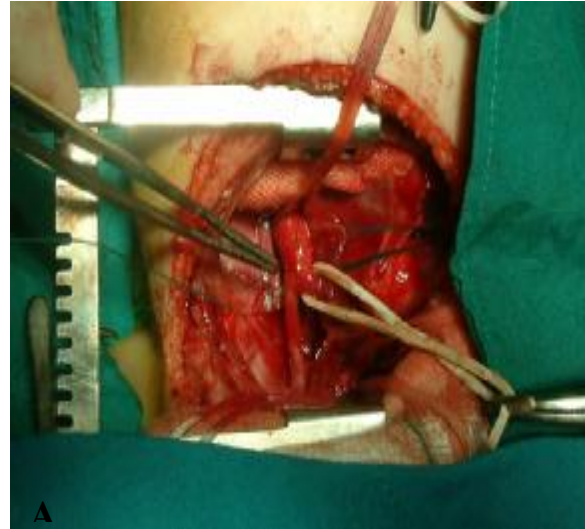


Fig. 2. A, B. Interrupted aortic arch type B from left thoracotomy approach

Complete absence of posterior and anterior communicating arteries together is very rare. After the complete release of the arch and descending aorta, we divided and suture ligated the PDA (Fig. 3).

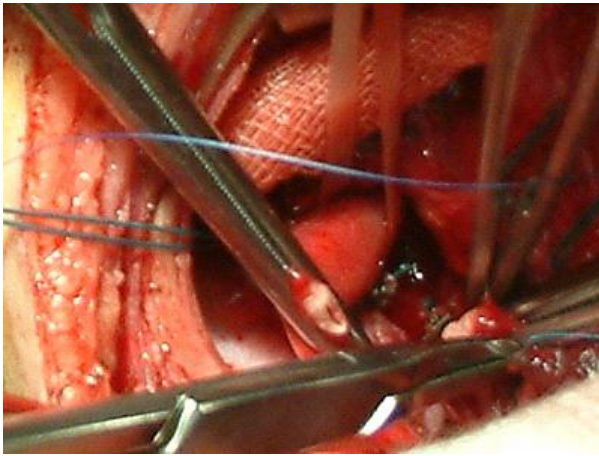


Fig. 3. Cutting PDA and double suturing pulmonary site.

A tension-free anastomosis provides a good continuity of the arch. The anastomosis in the posterior line was created with continuous stitches of prolene 5/0 and anteriorly with simple separate stitches. Our clamping time was under 20 minutes (Fig. 4).

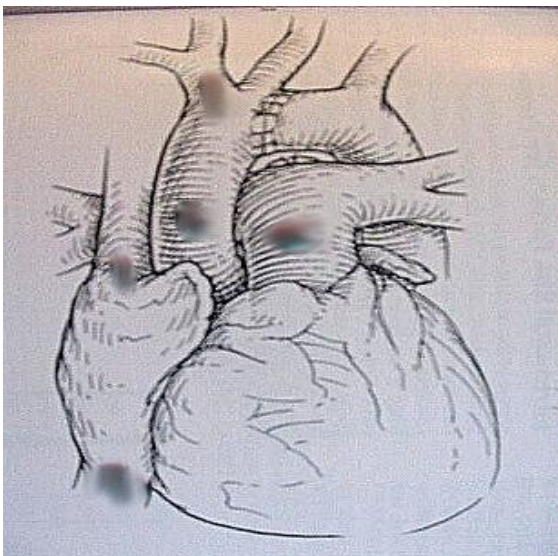


Fig. 4. Schematic view, end result

Pulmonary artery banding was done and repair of intracardiac anomaly was postponed to a later stage.

There was no gradient across the anastomosis by echocardiography two days after the operation, and blood pressure in the upper extremity and lower extremity was equal.

We conclude that interrupted aortic arch type B can be operated on successfully via the left thoracotomy approach without CPB and TCA in critically ill patients with coexisting intracardiac anomaly that needs complex operations such as a Fontan.

References

1. Cardiac Surgery. (Third edition) Kirklin/Barret-Boyes
2. Celoria GC, Patton RB. Congenital absence of the aortic arch. *American Heart Journal* 1959; 58: 407.
3. Ziemer G, Jonas RA, Perry SB, Freed MD, Castaneda AR. Surgery for coarctation of the aorta in the neonate. *Circulation* 1986; 74: 125.