

Reevaluation of Dipyridamole Thallium Scanning in Diagnosis of Myocardial Ischemia

M. Momtahn, MD; F. Rastgoo, MD and A. Sharifian, MD

Abstract

Objective- To reevaluate sensitivity, specificity and predictive value of dipyridamole thallium scanning in detecting myocardial ischemia, this study was performed.

Method- The study was carried out on 162 patients with typical chest pain and intermediate to high probability for CAD, who underwent coronary angiography and dipyridamole thallium scanning. 96 patients had coronary artery disease and 105 patients had positive scans for ischemia. In the coronary artery disease group, 82 patients had positive thallium scan and in normal coronary group, 23 patients had positive scan.

Result- The calculated sensitivity of the test for detecting CAD was about 85% and the specificity was about 64%. Positive and negative predictive values were about 75% and 78%, respectively. The sensitivity and specificity of the test for detecting LAD, RCA and LCX disease was 89% and 61%, 80% and 59% and 54% and 60%, respectively.

Conclusion- this study reveals that although dipyridamole thallium scan is sensitive for detection of myocardial ischemia, the specificity of the test is not remarkable (*Iranian Heart Journal 2004; 5(3):34-36*).

Key words: dipyridamole thallium scans ■ myocardial ischemia ■ coronary artery disease

Nowadays, dipyridamole myocardial perfusion scanning is increasingly used to detect myocardial ischemia. In this method, thallium 201 is used. The presence of various statistics in standard articles published about the sensitivity and specificity of dipyridamole myocardial perfusion scan sensitivity ranges from 85% to 95% and specificity ranges from 80% to 90%, and frequent false positive reports of ischemia in our patients, were an incentive for us to study the sensitivity and specificity of this method in our center.

Method and Material

This survey is a descriptive study in which the results of myocardial perfusion scan with SPECT method using thallium 201 with pharmacologic stress dipyridamole and the results of coronary angiography of patients have been used.

The patients who had typical chest pain and intermediate to high probability for coronary artery disease were referred for dipyridamole thallium scan and underwent coronary angiography.

After gathering the information, sensitivity and specificity of the myocardial perfusion scan with respect to angiography were calculated in single and multi-vessel disease patients. These data were compared to the results of published articles.

Results

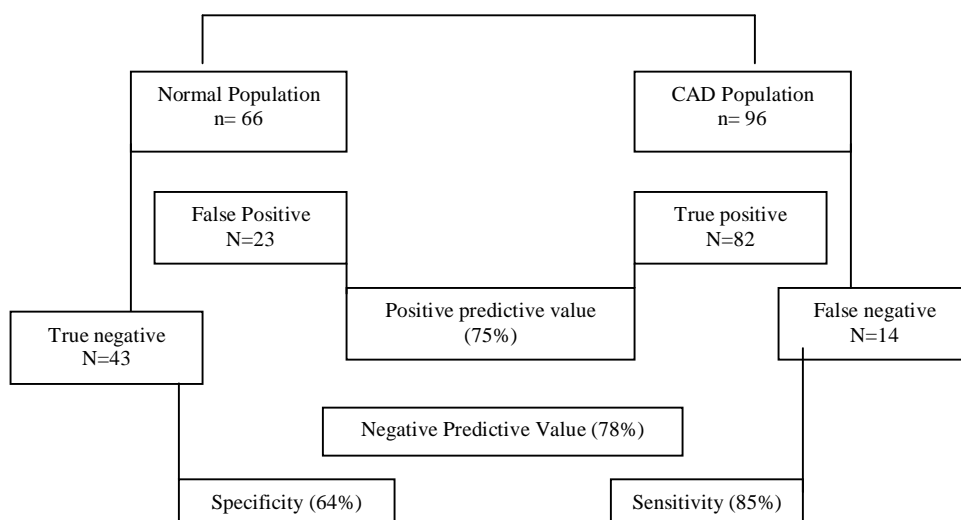
The clinical and angiographic characteristics are shown in Tables I and II. In CAD (coronary artery disease) group; 82 patients had positive thallium scan (true positive of 85%) and 14 patients had normal scans (false negative of 15%).

Table I: Clinical characteristics of 162 patients

Age	56±12
Male	81
FC II, III	74%
Smoking	24%
Lipid abnormality	17%
HTN	21%
DM	18%
FH	7%
BBB	8%
ESRD	2%

Table II: Angiographic characteristics of 162 patients

	No. %
Normal C. A	66 (40%)
SVD	25 (15%)
2VD	29 (18%)
3VD	35 (22%)
L M Lesion	7 (4%)

Table III: Dipyridamole thallium imaging results in 162 patients with intermediate to high probability for CAD.


In normal coronary group; 43 patients had normal scans (true negative of 65%) and 23 patients had positive scans (false positive of 35%) (Table III).

The sensitivity of dipyridamole perfusion scan of myocardium in the case of LAD (left anterior descending) disease is 89% and the specificity is 61%.

For RCA (right coronary artery) these figures are 80% and 59% and for LCX, 54% and 60.5%, respectively. The overall sensitivity and specificity of dipyridamole myocardial perfusion scan are 85% and 64%, respectively. Positive predictive value is 75% and negative predictive value is 78%.

Although the sensitivity of the test is similar in males and females (about 85%), the specificity is 67% in males versus 58% in the female gender.

In SVD (single vessel disease) group, the sensitivity is 79% and the specificity is 59%, whereas these figures in MVD (Multi vessel) group are 88% and 68%, respectively.

Discussion

In this study, we compared the myocardial perfusion scan using thallium 201 (Spect method with dipyridamole) and coronary angiography for evaluating myocardial

ischemia. 162 patients who had typical chest pain with intermediate to high probability for coronary artery disease were referred for dipyridamole thallium scan and underwent coronary angiography. Our findings demonstrate that sensitivity of dipyridamole thallium scan in our center (85%) is similar to the published data (85% - 90%),¹ but specificity is significantly lower (64% versus 85%).²

The low specificity of this test or presence of frequent false positive cases may be due to:

1. motion artifacts that should be prevented by the patient during imaging.³
2. attenuation artifacts: attenuation artifacts are the most common source of error⁴ in SPECT imaging. The supine position may cause inferior wall defects and attenuation by breast tissue can cause artifacts on SPECT imaging as well.
3. severe triple-vessel coronary artery disease can potentially result in false⁵ negative thallium. pattern as a result of a universal decrease in uptake with no apparent abnormality.
4. mitral valve prolapse, left ventricular hypertrophy and non ischemic cardiomyopathy (HCM⁵ and RCM)⁶ can cause false positive results.
5. dipyridamole can cause collapse of arterial wall due to decreased tonicity of vessels, especially in subendocardium and results in ischemic defect.⁷

6. preferential vasodilation of normal epicardial coronary arteries may reduce coronary blood flow across nonsignificant coronary arterial stenotic segments leading to collapse of this segment that could result in a false ischemic defect.⁸

Conclusion

Our findings demonstrate that although dipyridamole (Spect thallium 201) myocardial perfusion scan is highly sensitive for detection of myocardial ischemia (85%), its specificity is low (64%).

References

1. Beller: G A pharmacologic stress imaging. Clinical Nuclear Cardiology, 1995: 256-257.
2. Beller: G A Detection of CAD. Clinical Nuclear Cardiology 1995: 97-99.
3. Zaret, BC, Beller GA: Future development in single – photon emission computed tomography quantification and display. Nuclear Cardiology 1999: 104.
4. Zaret, BC, Beller GA: State of the art for CAD detection: thallium - 201. Nuclear Cardiology 1999: 256.
5. Braunwald A, Zipes P Z, Libby P: Nuclear Cardiology. In: Heart Disease. 6th edition. Philadelphia, W. B. Saunders Co., 2001: p. 287.
6. EE Depas quale, AC Nody, EG Depuey EV Garcia, et al: Amato quantitative rotational thallium- 201 tomography for identifying and localizing CAD. Circulation, 1988; 77: 316- 327.