

Metastatic Sarcoma Invasion through Pulmonary Vein to Left Atrium; an Unusual Way of Metastasis

M. Hekmat, M.D.; M. Foroughi, M.D.; H. R. Taghipour, M.D.; S. A. Hasantash, M.D.; M. M. Majidi Tehrani, M.D.; M. Beheshti Monfared, M.D.; M. K. Arabnia, M.D.; M. R. Nobahar, M.D.; M. Shahzamani, M.D.; N. Kachoueian, M.D.; A. M. Hallajzadeh, M.D.; and N. Rezaei, M.D.

Abstract

The usual ways of malignancy spreading to the heart are through the systemic circulation, coronary arteries, lymphatic channels and direct extension from adjacent organs.

This article presents two cases of metastatic sarcoma in the lung that invaded through the pulmonary vein to the left atrium and presented with signs of cerebrovascular accident.

It seems that there is a tendency for primary cardiac sarcoma to invade the pulmonary veins. Only sarcomas have this ability to invade and extend antegradely through the pulmonary veins to the left atrium; and even more surprisingly, only sarcoma can invade both sides of the heart in contrast to carcinoma, which nearly always invades the right heart (*Iranian Heart Journal* 2004; 5(4): 53-56).

Key words: Metastasis ■ sarcoma ■ invasion ■ atrium ■ pulmonary vein

Neoplasms of the heart can be divided to primary cardiac tumors arising in the heart and secondary cardiac tumors that have metastasized to the heart. Secondary involvement of the heart is relatively uncommon; ten to twenty percent of patients dying of disseminated cancer have metastatic involvement of the heart or pericardium. Surgical resection is seldom possible or advisable for these tumors, and surgical intervention is usually limited to drainage of malignant pericardial effusions and/or diagnostic biopsies.¹

Approximately ten percent of metastatic tumors eventually reach the heart or pericardium, and almost every type of malignant tumor has been known to do so.² Secondary neoplasms are 20-40 times more common than primary cardiac malignancies.³

Metastases may involve the pericardium,

epicardium, myocardium and endocardium in roughly that order of frequency.⁴

The most common means of spreading, particularly for melanoma, sarcoma and bronchogenic carcinoma, is via the blood stream and coronary arteries. Metastases can also reach the heart through lymphatic channels or through direct extension from adjacent organs. Cardiac metastases produce clinical symptoms in only 10% of afflicted patients. The most common symptom is pericardial effusion; occasionally, patients develop refractory arrhythmia or congestive heart failure.⁵

Surgical therapy is directed at providing symptomatic relief with minimum patient discomfort and hospital stay.

In this article, we report two patients with secondary left atrial malignancy extending through the pulmonary veins from the metastatic lung tumor.

Case reports

Case 1

Case 1 is a 21-year-old male with an osteosarcoma of the femur, which had metastasized to the left atrium through the pulmonary vein. The patient previously suffered from a femoral osteoblastic osteosarcoma, which was treated surgically (limb sparing resection and reconstruction) with multiple courses of chemotherapy 24 months before being referred to us. The patient was referred to our center in July 2003 for diagnosis and treatment of a left atrial mass. He had been well until 2 weeks before hospitalization due to a sudden headache, right-sided paresthesia, aphasia and weakness. Physical examination was otherwise unremarkable. Brain computed tomography (CT) scan revealed a diffuse hypodense area in middle cerebral artery, in the left fronto-parietal lobe, with no mass effect. Chest X-ray showed a diffuse radiolucent lesion containing a radio-opaque area in the right lung. Echocardiography demonstrated a mobile, pedunculated, polypoid lesion ($6\text{cm} \times 6\text{cm} \times 5\text{cm}$) in the left atrium and showing the characteristic myxomatous motion during the heart cycle.

At operation, the left atrium was opened via mid-sternotomy using cardio-pulmonary bypass. A large polypoid mass, white-to-pink in color, was found with multiple fragmentations. The mass was pedunculated and attached to the atrial wall, and the origins of the right inferior and right superior pulmonary veins were occluded. This tumor was apparently developed intravascularly and migrated through the right pulmonary veins to the left atrium (Figs. 1-3). Because of the involvement of the pulmonary veins, the right pleural cavity was opened: Multiple nodularity was present in the middle and inferior lobes with extensive adenopathy around the pulmonary hilum; therefore, a right pneumonectomy was performed. The

orifice of the right pulmonary veins (site of left atrium involvement) was resected and reconstructed with a pericardial patch. Postoperative recovery was uneventful. The histopathologic features of the atrium and lung tumor were identical to the primary malignancy. Despite postoperative chemotherapy, he died due to brain metastasis 6 months later. The unique aspect of this case is that the patient's symptoms were related to the involvement of the left atrium by pulmonary tumor through intravascular extension via the pulmonary veins.

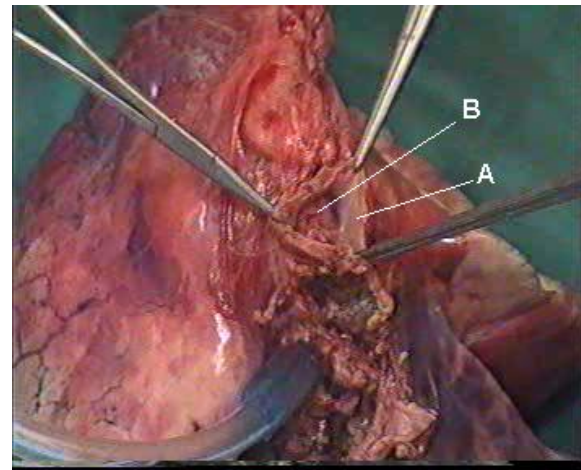


Fig. 1. Right lung specimen of case 1. A: the wall of right inferior pulmonary vein; B: the metastatic tumor, which occluded the lumen of the pulmonary vein.

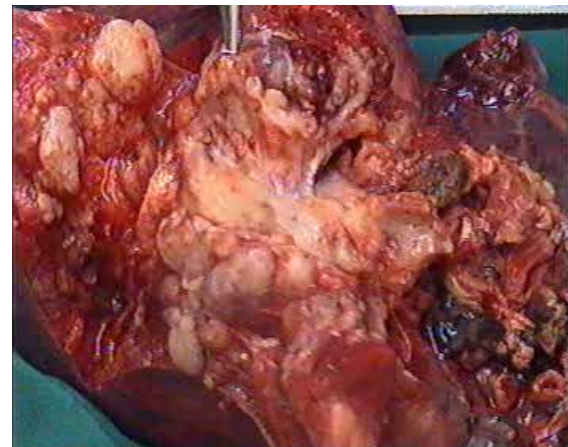


Fig. 2. The metastatic tumor, which occluded the lumen of pulmonary vein (case 1). A: the wall of right inferior pulmonary vein; B: the metastatic tumor.

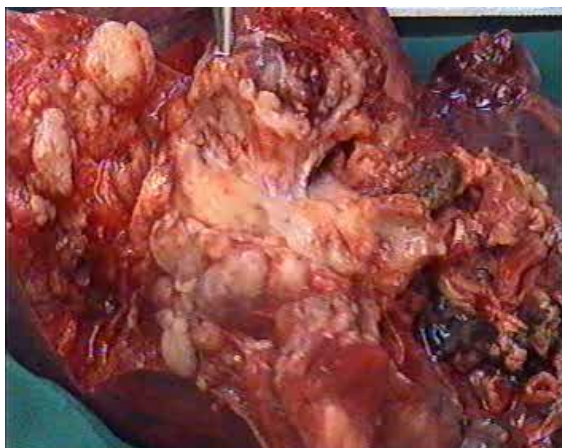


Fig. 3. Multiple metastatic nodules, which were disseminated in the whole right lung (case 1).

Case 2

Case 2 is a 42-year-old woman with liposarcoma of the small bowel. The patient had a history of laparotomy because of small bowel tumor 5 years before being referred to our center in September 2003 with dyspnea. The pathology examination demonstrated myxoid liposarcoma. She then received multiple courses of chemotherapy. Echocardiography demonstrated a pedunculated mass in the left atrium (Fig. 4).

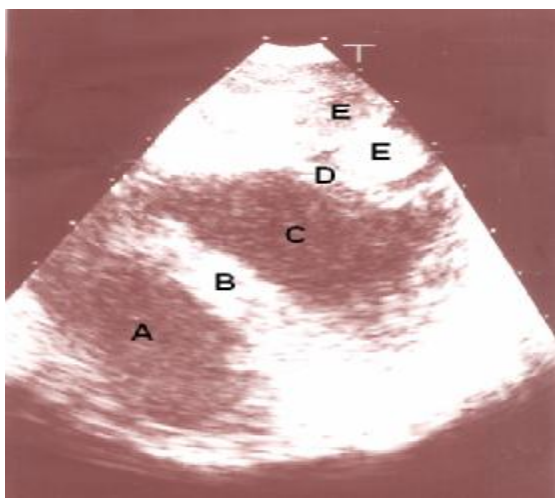


Fig. 4. The pedunculated, multiloculated mass in the left atrium of case 2 (long axis view of echocardiography). A: right ventricle; B: interventricular septum; C: left ventricle; D: mitral valve; E: mass.

At operation, 3 polypoid pedunculated masses of different sizes were found. They were attached to the posterior wall of the left atrium, between the right and left pulmonary veins, and had extension to the left pulmonary veins. The tumor was resected and shaved off from the atrial endocardial surface. The pathologic feature of the tumor was metastatic sarcoma.

Discussion

In addition to a thrombus, intracardiac mass lesions can also represent a primary cardiac tumor or a metastatic lesion. The echocardiographic appearance and location of a mass as well as annunciated clinical scenario provide useful clues regarding the cause. However, cardiac metastases are uncommon and difficult to diagnose and are most often found at autopsy.⁶

Osteosarcoma metastasizes to the heart quite rarely. Thirteen cases have been reported in the literature so far.⁷ The tendency of primary cardiac sarcoma to invade pulmonary veins has also been observed in the literature: polypoid mass of the left atrium with direct extension into the pulmonary veins^{8,9} and right atrial mass with posterior extension into the pulmonary veins¹⁰ have already been reported.

It seems that only sarcomas have this ability to invade both sides of the heart; in contrast to carcinomas, which always invade the right heart.⁸ Moreover, it seems that only sarcomas have this propensity to invade and extend antegradely through the pulmonary veins to the left atrium.¹¹⁻¹³

References

- 1- Reardon MJ, Smythe WR. Cardiac neoplasms. In: Cohen LH, Edmund LH. Cardiac Surgery in the Adult. New York, McGraw-Hill Co., 2003, pp. 1373-4.

- 2- McAllister HA Jr, Hall RJ, Cooley DA. Tumors of the heart and pericardium. *Curr Probl Cardiol* 1999; 24 (2): 57-116.
- 3- Hallahan DE, Vogelzang NJ, Borow KM, Bostwick DG, Simon MA. Cardiac metastases form soft-tissue sarcoma. *J Clin Oncol* 1986; 4: 1662-9.
- 4- Silverman NA. Primary cardiac tumors. *Am Surg* 1980; 191(2): 127-138.
- 5- Hanfling SM. Metastatic cancer to the heart. Review of the literature and report of 127 cases. *Circulation* 1960; 22: 474-83.
- 6- Huh J, Noh CI, Kim YW, et al. Secondary cardiac tumor in children. *Pediatr Cardiol* 1999; 20 (6): 400-3.
- 7- Yilmaz M, Farsak B, Altundag MK, Demircin M, Ozkutlu S, Pasaoglu I. Isolated cardiac metastasis of osteosarcoma. *J Exp Clin Cancer Res* 2000; 19 (3):395-7.
- 8- Toda R, Yotsumoto G, Masuda H, Sakata R, Umekita Y. Surgical treatment of malignant fibrous histiocyoma in the left atrium and pulmonary veins. *Surg Today* 2002; 32(3): 270-3.
- 9- Zanella M, Falconieri G, Bussani R, Sinagra G, Della Libera D. Polypoid osteosarcoma of the left atrium: report of a new case with autopsy confirmation and review of the literature. *Ann Diagn Pathol* 1998; 2 (3):167-72.
- 10- Lurito KJ, Martin T, Cordest T. Right atrial primary cardiac osteosarcoma. *Pediatr Cardiol* 2002; 23 (4):462-5.
- 11- Senbo J, Sasaki T, Hasegawa Y, et al. Resection of metastatic pulmonary lesion of osteosarcoma extended into left atrium and ventricle via the pulmonary vein. *Kyobu Geka* 1991; 44 (11):929-32.
- 12- Gowda RM, Khan IA, Mehta NJ, et al. Cardiac papillary fibrolastoma originating from pulmonary vein. *Angiology* 2002; 53(6): 745-8.
- 13- Zavala-Alarcon E, Sudhakar S, Gonzales LR, Patel R. Extension of pulmonary blastoma into the left atrium. *Mayo Clin Prac* 2001; 76(6): 657-60.