

Case Report

Successful Ablation of Drug-Resistant PJRT Utilizing 3D Mapping in an Infant: A Case Report

Mohammad Rafikhorgami¹, MD; Feisal Rahimpour^{2*}, MD;
Davood Ramezani Nezhad¹, MD

ABSTRACT

Permanent junctional reciprocating tachycardia (PJRT) is a rare form of supraventricular tachycardia that primarily affects infants and young children. PJRT is a type of reentrant tachycardia, often involving an accessory pathway called the “Kent bundle.” This accessory pathway enables electrical impulses to bypass the normal electrical conduction system, leading to a rapid and abnormal heart rhythm. Common symptoms of PJRT include palpitations, fatigue, and shortness of breath, with infants frequently experiencing feeding difficulties. PJRT management usually consists of antiarrhythmic medications, such as β -blockers or calcium channel blockers, to control the heart rate. However, in cases where medications are ineffective in suppressing the arrhythmia, known as drug-resistant PJRT, alternative treatment options must be considered. PJRT is characterized by a re-entry pathway involving the atrioventricular node and an accessory pathway, resulting in incessant and rapid heart rates. In instances where medications are unsuccessful in controlling the arrhythmia, ablation utilizing 3D mapping technology offers a promising therapeutic option. This article examines a case where an infant with drug-resistant PJRT for 1 year was successfully treated with ablation, facilitated by the use of a 3D mapping system. (*Iranian Heart Journal 2024; 25(3): 80-84*)

KEYWORDS: Permanent junctional reciprocating tachycardia, 3D mapping, Accessory pathway, Ablation

¹ Rajaie Cardiovascular Medical and Research Center, Iran University of Medical Sciences, Tehran, IR Iran.

² Emam Reza Hospital, Mashhad University of Medical Science, Mashhad, IR Iran.

* **Corresponding Author:** Feisal Rahimpour, MD; Rajaie Cardiovascular Medical and Research Center, Iran University of Medical Sciences, Tehran, IR Iran.

Email: Rahimpourf1@mums.ac.ir

Tel: +989133815233

Received: December 10, 2023

Accepted: February 10, 2024

Permanent junctional reciprocating tachycardia (PJRT) is a form of reentrant tachycardia that often involves an accessory pathway called the “Kent bundle.” This accessory pathway allows electrical impulses to circumvent the normal electrical conduction system, leading to rapid and abnormal heart rhythms. Common symptoms of PJRT include palpitations, fatigue, and shortness of breath, with infants frequently experiencing feeding

difficulties. PJRT management generally involves the use of antiarrhythmic medications, such as β -blockers or calcium channel blockers, to regulate the heart rate. Nonetheless, in cases where medications are ineffective in suppressing the arrhythmia, known as drug-resistant PJRT, alternative treatment methods must be considered. Over the past few years, the field of cardiac electrophysiology has witnessed significant advancements, particularly with the

introduction of 3D mapping systems. These advanced technologies enable precise mapping of the heart's electrical signals, as well as identification of abnormal pathways or areas responsible for the arrhythmia.

In this case study, we present a successful ablation of drug-resistant PJRT in a 12-month-old infant. The patient, who was experiencing incessant tachycardia despite multiple antiarrhythmic medication trials, necessitated an alternative therapeutic approach. Given the complexity of the arrhythmia and the patient's young age, it was decided that 3D mapping technology, specifically the NavX system, would facilitate the ablation procedure.

CASE REPORT

A 12-month-old male infant, weighing 10 kg and measuring 60 cm in length, presented with incessant drug-resistant narrow QRS, long-RP tachycardia, and a superior P-wave axis since birth (Fig. 1).

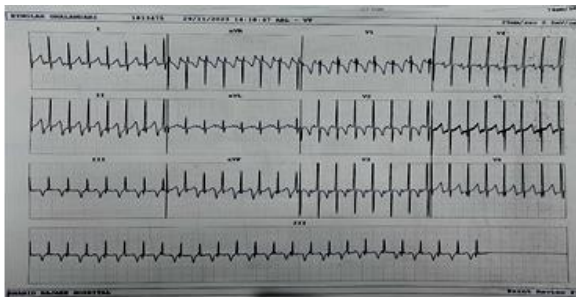
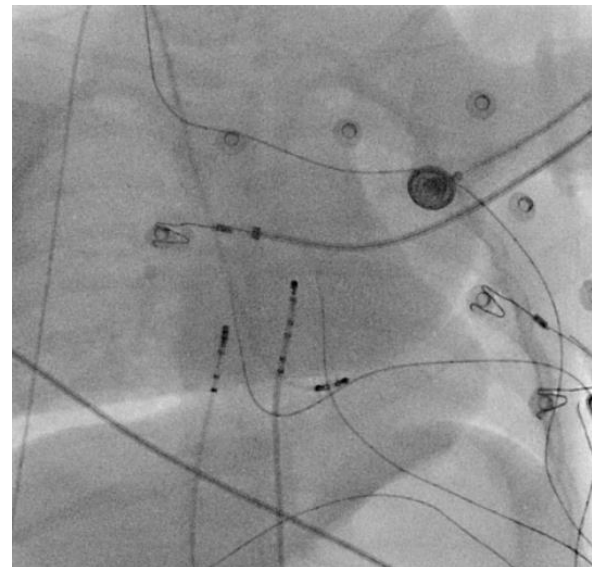


Figure 1: The image illustrates a 12-lead ECG with narrow QRS, long-RP tachycardia, and a superior P-wave axis.

The patient was otherwise healthy, without any confirmed extracardiac manifestations. Laboratory tests revealed normal electrolyte levels and thyroid hormones. Treatment with amiodarone, flecainide, propranolol, and sotalol, both as monotherapy and in combination, proved ineffective. Echocardiographic examination identified a small patent ductus arteriosus and a small atrial septal defect. Serial echocardiography demonstrated a gradual decline in the

function of both ventricles, with a recent left ventricular ejection fraction of 45%. Holter monitoring confirmed the persistent nature of the arrhythmia for most of the time.

Following the acquisition of informed consent, the patient was scheduled for an electrophysiological study under general anesthesia. Due to challenging venous access, we were able to access only 2 veins, despite the requirement of at least 3. One 6 Fr sheath was inserted through the right femoral vein, and one 5 Fr sheath was inserted through the right subclavian vein. Under conventional fluoroscopy and sonography, a catheter (St Jude Medical) was advanced into the right atrium for ablation, while another catheter was inserted into the right ventricle for mapping. The NavX system provided clear visualization of anatomical structures, including the atrioventricular (AV) node and accessory pathway, offering valuable guidance throughout the procedure. Additionally, we gained access to the femoral artery for blood pressure monitoring. To enhance the electrophysiological study and obtain atrial signals, we advanced a quadripolar 5 Fr catheter through the femoral artery to the aorta, placing it near the posterior left atrium for arterial signal recording (Fig. 2). Appropriate signal mapping and maneuvers were then performed.



approximately 3 hours. A subsequent adenosine test performed post-ablation revealed no evidence of a VA connection (Fig. 6). The procedure proved successful, leading to the complete elimination of the PJRT. Post-ablation, the patient maintained sinus rhythm, with no reported instances of tachycardia recurrence. Following a 3-day hospital stay, the infant was discharged in good health and with a stable sinus rhythm, as verified by 24-hour Holter monitoring.

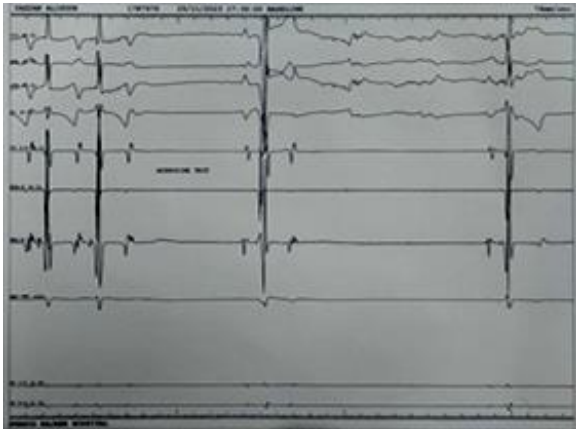

Figure 6: The image presents an intracardiac ECG, showcasing the results of an adenosine test following a successful ablation procedure.

DISCUSSION

PJRT, a form of SVT, exhibits unique characteristics such as retrograde-only decremental conduction accessory pathways, distinguishing it from classic accessory pathways. These distinct features contribute to the incessant nature of tachyarrhythmia. In infants, PJRT may be misdiagnosed as normal sinus tachycardia due to its relatively slow rate of approximately 150 to 160 beats per minute. Another noteworthy characteristic of PJRT is its long RP tachycardia, which results from slow retrograde conduction. While PJRT shares similarities with other accessory pathways in its responsiveness to intravenous adenosine, it often recurs immediately, potentially leading to misinterpretation as refractory

tachyarrhythmia. Misdiagnosis and delayed identification of these distinct characteristics may result in heart failure or other complications. In most instances, medical therapy effectively manages infantile arrhythmias.³ Catheter ablation, although considered a last resort, is typically reserved for a limited number of cases. Managing PJRT with antiarrhythmic drugs can be difficult, as reported patients who achieved control with medical therapy required multiple drugs used in combination.⁴ In larger children with PJRT, RF ablation is regarded as the gold-standard treatment, boasting success rates between 80% and 90%, as well as low complication and recurrence rates.^{2,4} However, the efficacy of ablation in neonates and infants remains uncertain,² prompting many centers to favor a medical management approach. Catheter ablation during infancy presents several challenges, including small body size, difficult vein access, anesthesia considerations, and higher complication rates such as AV node block, tamponade, and coronary artery injury. Therefore, careful case selection should be conducted after a comprehensive evaluation. Our patient underwent various medical treatment protocols for 1 year without a significant response, and due to reduced cardiac function, we decided to proceed with catheter ablation.

In our case, the retrograde conduction accessory pathway was identified in the typical location of the accessory pathway - the mouth of the coronary sinus. This finding aligns with a study conducted by Kang et al² that assessed 194 PJRT patients, 140 of whom received catheter ablation. Among these patients, 113 individuals had an accessory pathway in the right posteroseptal region. A study conducted by Akdeniz et al⁶ emphasized the efficacy and potency of transcatheter cryoablation in treating refractory SVT in infants.

Nevertheless, the application of cryo catheters in small infants is limited due to their relatively large size and challenges with maneuverability.

In our case, the PJRT diagnosis was confirmed through a comprehensive evaluation of the patient's medical history, ECG characteristics, and specialized maneuvers performed in the electrophysiology lab. It is essential to consider other significant differential diagnoses for long RP narrow QRS tachycardia, namely atypical AVNRT and atrial tachycardia. We ruled out these possibilities by conducting appropriate electrophysiological studies. Notably, no single absolute criterion exists for diagnosing PJRT through electrophysiology studies, and there may be some overlap between diagnostic maneuvers. Therefore, it is crucial to consider all maneuvers collectively to establish an accurate diagnosis.

CONCLUSIONS

When managing drug-resistant PJRT in infants, traditional medication often fails to control arrhythmia effectively. In such cases, ablation assisted by advanced 3D mapping systems offers a promising therapeutic approach. The cutting-edge NavX 3D mapping system enables precise localization of abnormal pathways, allowing for targeted ablation of the accessory pathway responsible for tachycardia. This case study exemplifies the clinical effectiveness of 3D mapping-assisted ablation in treating drug-resistant PJRT in infants, highlighting its potential as a viable solution when medical therapy proves inadequate.

Conflict of Interest

The authors declare that they have no conflicts of interest to disclose.

Acknowledgments

The authors would like to express their gratitude to the electrophysiology staff at the Rajaie Cardiovascular Medical and Research Center for their contributions to this research.

Patient Permission/Consent Statement

The patient provided informed consent for the publication of this case report, and the procedure was carried out in accordance with the ethical policy of the center.

REFERENCES

1. Ilhan O, Hakan N, Kayilioglu H, Kirli U, Karacan M, Olgun H. Treatment of Permanent Junctional Reciprocating Tachycardia in a Preterm Neonate: Case Report. *J Pediatr Intensive Care*. 2021; 10(4):317-22.
2. Kang KT, Potts JE, Radbill AE, La Page MJ, Papagiannis J, Garnreiter JM, et al. Permanent junctional reciprocating tachycardia in children: A multicenter experience. *Heart Rhythm*. 2014; 11(8):1426-32.
3. Dalili M, Rahimpour f, Catheter ablation for an incessant arrhythmia in a preterm low-weight neonate, *Journal of Cardiology Cases* Volume 28, Issue 6, December 2023, Pages 253-256
4. Kylat RI, Samson RA. Permanent junctional reciprocating tachycardia in infants and Children. *J Arrhythm*. 2019; 35(3):494-8.
5. Vaksman G, D'Hoinne C, Lucet V, Guillaumont S, Lupoglazoff JM, Chantepie A, et al. Permanent junctional reciprocating tachycardia in children: a multicentre study on clinical profile and outcome. *Heart*. 2006; 92(1):101-4.
6. Akdeniz C, Kiplapınar N, Sengül FS, Tuzcu V. [Successful catheter ablation in a newborn with supraventricular tachycardia resistant to medical therapy]. *Anadolu Kardiyol Derg*. 2012; 12(5):440-2.