

Case Report

Hemoptysis After Angiography as the First Manifestation of Hydatidosis: A Case Report

Mohammadhosein Ranjkesh¹, MD; Mostafa Eslamimahmoudabadi¹, MD;
Emad Dadgar¹, MD; Seyed Hosein Sharubandi^{2*}, MD

ABSTRACT

Background: Hydatid disease, a prevalent health concern in livestock-producing nations, results from *Echinococcus* larval stages infection. The disease can affect multiple organs, including the liver, lungs, muscles, bones, kidneys, spleen, brain, and heart. Symptoms range from cough, hemoptysis, and shortness of breath to retention pneumonia, atelectasis, and congestion. Diagnosis involves a combination of patient history, physical examinations, and diagnostic tools such as X-rays and computed tomography scans. Treatment typically entails surgical intervention and albendazole therapy.

Case Presentation: A 55-year-old woman with a history of hyperlipidemia and dog care was referred to the Baqiyatallah Heart Clinic for recurrent episodes of chest pain. She was subsequently diagnosed with ischemic heart disease and given standard care, including heparin, for acute coronary syndrome. Upon further evaluation via angiography, stenosis was detected in the left anterior descending artery, prompting a referral for thoracic surgery. After a week-long recovery period, angioplasty and stent placement were carried out, with observations indicating normal right and left ventricular sizes.

Discussion and Conclusions: Pulmonary hydatid cysts, frequently resulting from prolonged contact with domestic animals, are typically marked by coughs. Treatment approaches encompass surgical interventions and benzimidazole administration following the procedure. Surgical treatment, particularly thoracotomy resection and pharmacotherapy, is the preferred approach. Hemoptysis, an uncommon occurrence in adults, can also arise from anticoagulant usage. (*Iranian Heart Journal 2025; 26(1): 102-106*)

KEYWORDS: Hemoptysis, Angiography, Hydatidosis, Hydatid cyst

¹ Student Research Committee, Baqiyatallah University of Medical Sciences, Tehran, IR Iran.

² Atherosclerosis Research Center, Baqiyatallah University of Medical Sciences, Tehran, IR Iran.

* **Corresponding Author:** Seyed Hosein Sharubandi, MD; Atherosclerosis Research Center, Baqiyatallah University of Medical Sciences, Tehran, IR Iran.

Email: sh.sharoo1975@gmail.com

Tel: +989177756159

Received: May 04, 2024

Accepted: July 28, 2024

H ydatid disease is a common health problem in countries with high rates of livestock production and is a considerable zoonosis worldwide. It occurs

due to the infection of the larval stages of taeniid cestodes of the genus *Echinococcus*.¹ Hydatid cysts can be found in any part of the body, with the most common sites being the

liver (50%–70%), lungs (5%–30%), muscles (5%), bones (3%), kidneys (2%), spleen (1%), brain (1%), and heart (0.5%–2%).² Hydatid cysts can grow in the lungs due to their elasticity and compliance and can range from 1 to 15 cm in size.³ Intrathoracic extrapulmonary hydatidosis is uncommon and may involve the pleura, mediastinum, heart, diaphragm, and chest wall.⁴ Clinical signs and symptoms differ based on the number, size, location, and impact of the cysts. A significant proportion of patients with hydatidosis may remain asymptomatic until space-occupying effects appear in the involved organs.⁵ Cyst-associated symptoms and signs include coughs, hemoptysis, shortness of breath, retention pneumonia, atelectasis, and congestion of the superior vena cava due to compression of surrounding tissues. The detachment of the parasitic cyst membrane from the adventitia and the formation of patent cystic-bronchial fistulas can give rise to cyst-associated complications. These complications may manifest as the expectoration of cyst content, anaphylactic reactions, the aspiration of cyst content leading to asphyxia and eosinophilic pneumonia resulting from aspirated parasitic material, retrograde bacterial infection, and lung abscess. The rupture of a cyst into the pleural space can lead to pneumothorax and pleural dissemination.⁶

Initial diagnosis can be made based on history, physical examinations, and other tests. Thoracic X-ray and computed tomography (CT) scans can reveal abnormal findings in patients with cysts, although there are no specific parenchymal lesions for hydatid disease of the lung. The use of fiberoptic bronchoscopy has been reported for effective diagnosis, particularly in cases of ruptured cysts that show characteristic changes in radiographic imaging as a result of air entering the cyst and separating the cyst layers from the surrounding host tissue. Serology studies may be useful but do not appear to be highly

sensitive.⁷ The rupture of a cyst significantly impacts the *Echinococcus* IgG test's positivity. Despite pulmonary hydatid cysts being benign in nature, their ruptured or complicated forms can display radiological features resembling those of lung cancer. Clinical, radiological, and bronchoscopic findings of pulmonary hydatid cysts cannot be distinguished from lung cancer, particularly in elderly patients.⁸ Hydatid cysts are diagnosed through pathological studies conducted after the surgical removal of the cyst.⁹

Treatment typically involves surgery with concurrent albendazole therapy and generally yields excellent results. Early diagnosis of this condition is crucial to avoid serious complications.^{3, 6, 10}

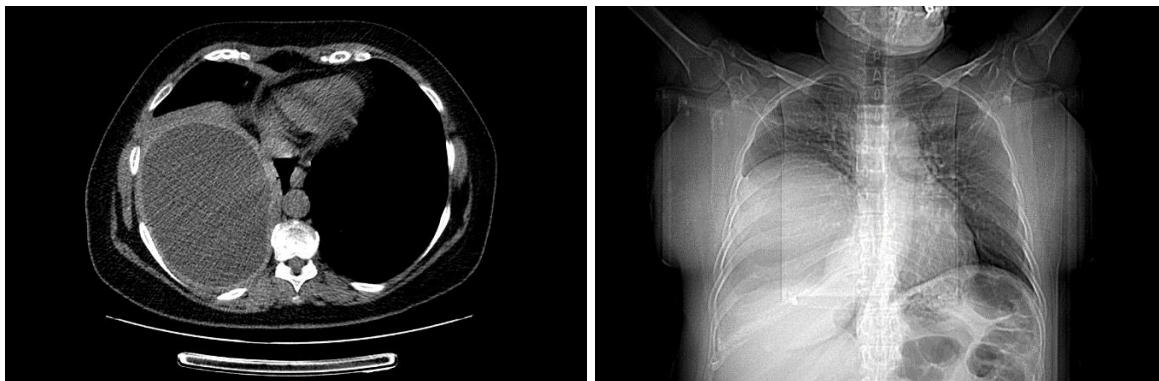
In this case report, we present our clinical and surgical expertise in diagnosing and treating pulmonary hydatidosis. Our findings contribute to the existing body of knowledge and may provide valuable insights for healthcare professionals encountering similar cases in their clinical practice.

CASE REPORT

A 55-year-old woman without any history of ischemic heart disease was referred to Baqiyatallah Heart Clinic. She presented 2 atypical chest pain attacks with mild dyspnea and left hemithorax heaviness radiating to the left shoulder within the last few days. She had hyperlipidemia with a positive family history of ischemic heart disease in both parents and a history of dog care for about 10 years. In her medication history, she only reported the use of atorvastatin tablets once daily. Upon auscultation, S1 and S2 heart sounds were audible, while her ECG demonstrated a normal sinus rhythm. Given the findings of septum ischemia with an ejection fraction of 50% in stress echocardiography assessments, she was considered a suitable candidate for angiography. Before her admission, standard care for acute coronary syndrome was

administered. Additionally, intravenous heparin at a dosage of 10,000 units, along with standard-dose clopidogrel, was prescribed before her angiography procedure. Angiography revealed significant stenosis in the mid-segment of the left anterior descending (LAD) artery, characterized by good runoff and right dominance. The ultimate recommendation from this investigation was to perform percutaneous coronary intervention on the LAD. Nonetheless, during her time in the recovery room, approximately an hour following the angiography procedure, she began experiencing mild hemoptysis with the expectoration of light blood, accompanied by distress and frequent productive coughing episodes. Upon recording vital signs, tachycardia was observed with a heart rate of 110 bpm. Her blood pressure was 146/85 mm Hg, her oxygen saturation was 96%, and she did not present with fever (36.6 °C). The hemoptysis and related symptoms persisted for roughly half an hour. Given these clinical manifestations, the decision was made to postpone the patient's angioplasty procedure. Protamine sulfate was administered intravenously over 10 minutes to counteract the anticoagulant effects of heparin. Subsequently, a pulmonologist was consulted to assess the patient's respiratory symptoms. In light of her history of chronic coughs and the sudden onset of hemoptysis, a CT scan was performed. The CT scan revealed the

presence of a faint ground glass opacity and a well-defined cystic lesion with regular borders, measuring 14 × 10 cm, located in the right lower lobe. Additionally, a compressive effect on the diaphragmatic dome was noted, along with displacement toward the lower side (Figs. 1 & 2). Following the chest CT scan findings, the patient was referred to a thoracic surgeon for further management. The decision was made to proceed with surgery due to the size and associated complications of the cyst. In preparation for the procedure, both aspirin and Plavix were discontinued, while albendazole was prescribed to address the parasitic infection. One week after the initial diagnosis, the patient underwent a thoracotomy and pneumolysis, along with the resection of the right hydatid cyst. This procedure was performed under the intercostal nerve block at the fourth level. Upon completion of the recovery period, the patient was restarted on aspirin and Plavix to reduce the risk of thrombotic events. One week post-surgery, she was transferred to the catheterization laboratory, where angioplasty was successfully performed. During the procedure, 2 stents were placed in the mid and distal segments of the LAD. A subsequent echocardiography examination, performed a day after stenting, revealed normal right and left ventricular sizes and an ejection fraction of 55%



Figures 1 and 2: The images show the patient's diagnostic chest computed tomography scan.

DISCUSSION

A significant proportion of individuals diagnosed with pulmonary hydatid cysts have a history of prolonged contact with domestic animals, which often serve as the source of *Echinococcus* infection. While smaller cysts may remain asymptomatic, the most common clinical symptom experienced by adults with pulmonary hydatid cysts is a persistent cough, with a reported prevalence ranging from 54% to 79%.¹¹

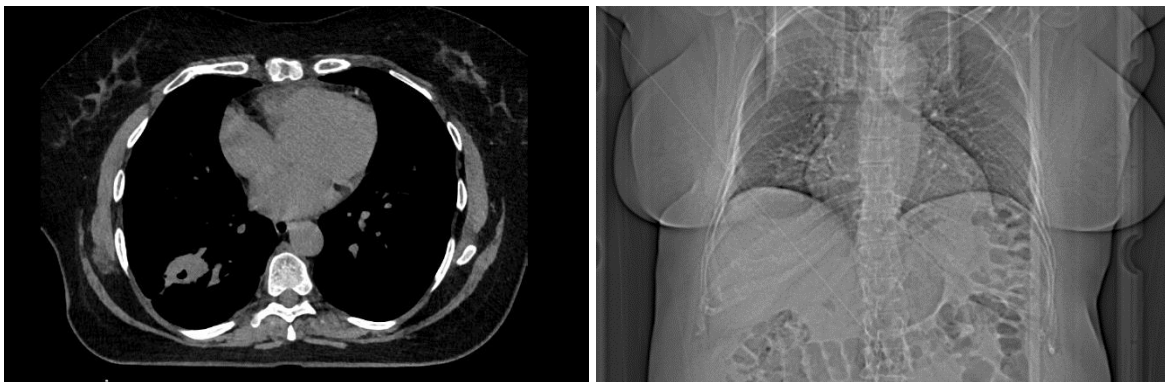
The primary treatment modality for pulmonary hydatid cysts is surgical intervention.¹² Cyst resection through thoracotomy is an optimal surgery.¹³ Pharmacotherapy with benzimidazoles, such as albendazole and mebendazole, is another option that can be beneficial in some patients. The patient reported a history of chronic coughs spanning several years, without any history of smoking. Prior to the CT scan, there was no documented evidence of a hydatid cyst. We believed that the hemoptysis experienced by the patient was a result of the anticoagulant drug (heparin) administered before angiography. This event prompted further investigation into the cause of hemoptysis through a CT scan, which

ultimately revealed a pulmonary hydatid cyst. Given the size and associated complications, the patient was deemed a suitable candidate for surgical intervention to address the cyst.

Hemoptysis is a relatively common presentation in adult cases, with a prevalence of up to 70%, while it remains quite rare in pediatric cases. The primary mechanisms responsible for hemoptysis include bronchial erosion due to pressure, secondary infections leading to obstruction, and erosion of major blood vessels.¹⁴ Moreover, there is a potential risk of hemoptysis following the use of anticoagulant medications, even in instances involving pre-existing lesions.¹⁵

Follow-up

One year after the initial visit, the patient reported no symptoms such as chest pain or dyspnea upon exertion. There was a marked improvement in her chronic coughs. Echocardiography findings indicated no signs of cardiomegaly or reduced left ventricular function. Additionally, a follow-up chest CT performed 1 year post-surgery showed no pathological findings apart from the surgical site (Figs. 3 & 4).



Figures 3 and 4: The images showcase the patient's follow-up chest computed tomography scan.

CONCLUSIONS

In regions with a high prevalence of hydatid disease and among individuals with a history of prolonged contact with domestic and

livestock animals, hydatid cysts should be considered as a possible cause of chronic cough. It is important to note that hydatid cysts can be asymptomatic and may be

incidentally discovered during the diagnostic workup for other conditions, such as cardiovascular diseases or inflammatory lung diseases. The most effective treatment approach for hydatid cysts involves surgical intervention, combined with postoperative administration of benzimidazoles to minimize the risk of recurrence.

REFERENCES

1. Nakao M, Lavikainen A, Yanagida T, Ito A. Phylogenetic systematics of the genus *Echinococcus* (Cestoda: Taeniidae). *Int J Parasitol.* 2013; 43(12-13):1017-29.
2. Sirlak2 NDYM. Cardiac Hydatid Cysts-Review of Recent Literature. *Journal of Veterinary Medicine and Research.* 2017.
3. Thapaliya P, Ahmad T, Abid A, Sikander N, Mazcuri M, Ali N. Management Outcome in Simple and Complex Hydatid Cysts of Lung. *Cureus.* 2020;12(12):e12212.
4. Saeedan MB, Aljohani IM, Alghofaily KA, Loutfi S, Ghosh S. Thoracic hydatid disease: A radiologic review of unusual cases. *World J Clin Cases.* 2020;8(7):1203-12.
5. Khalili N, Iranpour P, Khalili N, Haseli S. Hydatid Disease: A Pictorial Review of Uncommon Locations. *Iran J Med Sci.* 2023;48(2):118-29.
6. Weber TF, Junghanss T, Stojković M. Pulmonary cystic echinococcosis. *Curr Opin Infect Dis.* 2023;36(5):318-25.
7. Ulaş AB, Eroğlu A, Aydın Y, Araz Ö, Ahmed A. The diagnostic value of fiberoptic bronchoscopy in ruptured lung hydatid cysts. *Türk Gogus Kalp Damar Cerrahisi Derg.* 2019;27(3):350-4.
8. Aydın Y, Altuntas B, Kaya A, Ulas AB, Uyanık MH, Eroglu A. The Availability of *Echinococcus* IgG ELISA for Diagnosing Pulmonary Hydatid Cysts. *Eurasian J Med.* 2018;50(3):144-7.
9. Kassahun Tadele A, Israel Korga T, Melis Nisiro A, Abebe Ayele S. Rare Case Report on Hydatid Cyst of Breast. *Pathology and Laboratory Medicine International.* 2022;14(null):33-6.
10. Rodríguez-Laiz G, Melgar P, Bolufer S, Navarro Martínez J, Ramia JM. Liver and lung hydatid cysts with transdiaphragmatic rupture treated by radical surgery. *Ann R Coll Surg Engl.* 2022;104(5):e125-e7.
11. Rawat S, Kumar R, Raja J, Singh RS, Thingnam SKS. Pulmonary hydatid cyst: Review of literature. *Journal of Family Medicine and Primary Care.* 2019;8(9).
12. Bagheri R, Haghi SZ, Amini M, Fattahi AS, Noorshafiee S. Pulmonary hydatid cyst: analysis of 1024 cases. *Gen Thorac Cardiovasc Surg.* 2011;59(2):105-9.
13. Athanassiadi K, Kalavrouziotis G, Loutsidis A, Bellenis I, Exarchos N. Surgical treatment of echinococcosis by a transthoracic approach: a review of 85 cases. *Eur J Cardiothorac Surg.* 1998;14(2):134-40.
14. Sarkar M, Pathania R, Jhobta A, Thakur BR, Chopra R. Cystic pulmonary hydatidosis. *Lung India.* 2016;33(2):179-91.
15. Seyyedi SR, Sadr M, Chitsazan M, Abedini A, Sharif-Kashani B. Angioembolization in massive hemoptysis for a patient with acute coronary syndrome and history of hydatid cyst. *J Cardiol Cases.* 2021;23(5):231-3.