

Case Report

Double Left Anterior Descending Artery Arising From the Left and Right Coronary Arteries in a Patient Undergoing Preoperative Evaluation Before Elective Noncardiac Surgery

Seyed Kianoosh Hosseini¹, MD; Masoud Fakhraei¹, MD;
Siamak Khavandi², MD; Soheila Khavandi^{1*}, MD

ABSTRACT

A double left anterior descending coronary artery originating from the left and right coronary arteries is a rare congenital coronary artery anomaly. In the present report, we describe a patient with a double left anterior descending coronary artery arising from the left and right coronary arteries. To our knowledge, only a limited number of such cases have been reported in the literature so far. (*Iranian Heart Journal 2016; 17(2):44-47*)

Keywords: Coronary artery anomaly ■ Double left anterior descending artery ■ Coronary artery angiography

¹ Department of Cardiology, Shariati Hospital, Tehran University of Medical Sciences, Tehran, I.R. Iran.

² School of Medicine, Tehran University of Medical Sciences, Tehran, I.R. Iran.

*Corresponding Author: Soheila Khavandi, MD

E-mail: dr.khavandi@gmail.com

Tel: 09143104117

Received: August 31, 2015

Accepted: April 11, 2016

Congenital coronary artery anomalies are rare, with a percentage of about 0.2%–1% in angiographic studies.¹⁻³ Simultaneously, they are of clinical interest insofar as they can result in ischemic events and even sudden death.⁴⁻⁶ However, a dual left anterior descending artery (LAD) originating from the left coronary artery (LCA) and the right coronary artery (RCA) is a very rare asymptomatic coronary anomaly and is detected incidentally during angiography. The presence of a short LAD and an avascular area in the distribution of the LCA could lead us to this anomaly.^{7,8} In this report, we present an unusual case of a double LAD, with the first vessel arising from the left

main coronary artery and the second arising from the proximal RCA.

CASE REPORT

An 84-year-old woman was admitted to our hospital for elective hysterectomy. The patient had no dyspnea or exertional chest pain. She had a history of systemic hypertension. The physical examination did not reveal any abnormal findings. Blood pressure was 120/80 mm Hg, and pulse rate was 80 beats/min. Cardiac and lung auscultation was normal. ECG showed normal sinus rhythm and left bundle branch block. Chest X-ray was normal. Routine

blood and biochemical laboratory tests demonstrated iron deficiency anemia.

The patient underwent preoperative Dobutamine stress echocardiography, which revealed a biphasic response in the base and mid posterior, mid lateral, and mid anteroseptal regions at 15 $\mu\text{g}/\text{kg}/\text{min}$ and a hyperkinetic response in the other myocardial segments—in favor of ischemia at the above-mentioned regions.

Coronary angiography was performed via the right femoral artery applying the Judkins method. A selective injection of the contrast

media into the LCA manifested a normal left main and left circumflex artery (LCx). The LCx delivered 2 obtuse marginal branches, neither of which had significant narrowing. A short LAD arose from the left main, ran normally, and terminated immediately at the initial part of the anterior interventricular groove after giving off the first septal and diagonal branches. The area that is normally perfused by the mid and distal sections of the LAD had no vessels including the collateral circulation. This short LAD was meanwhile free of considerable narrowing (Fig. 1).

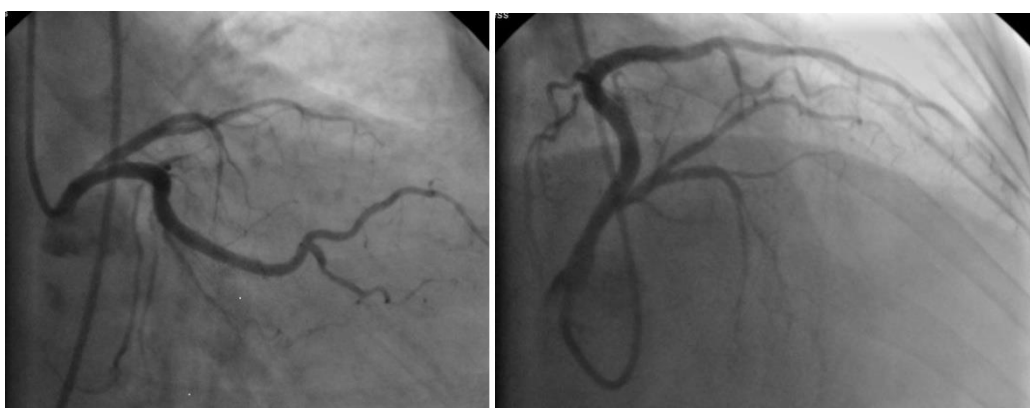

Figure 1. A short left anterior descending artery, originating from the left main and terminating immediately at the initial part of the anterior interventricular groove after giving off the first septal and diagonal branches.

Selective RCA angiography with an RCA Judkins catheter technique disclosed a normal RCA and another vessel arising from the origin of the RCA. This abnormal vessel—which was considered an extra LAD—turned

to the left, moved sharply downward to pass over the mid and distal parts of the anterior interventricular groove, and gave rise to multiple small septal branches (Fig. 2).

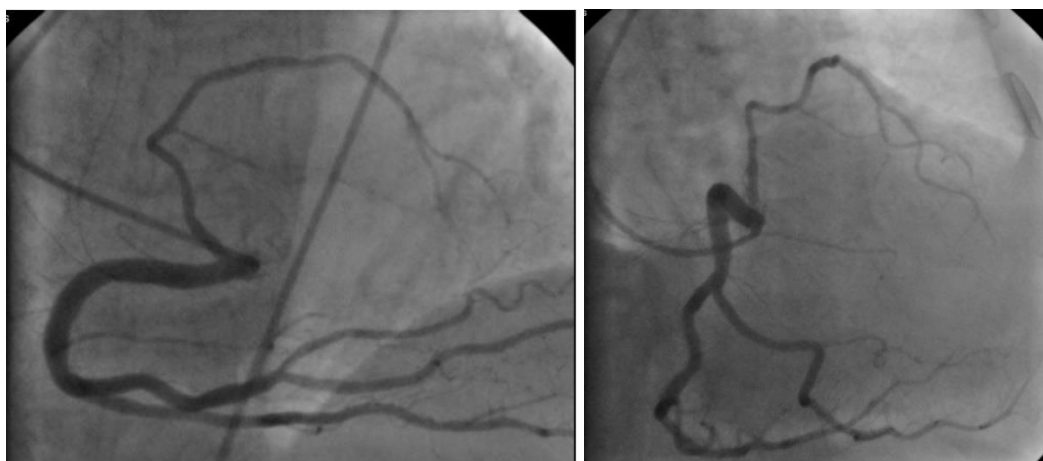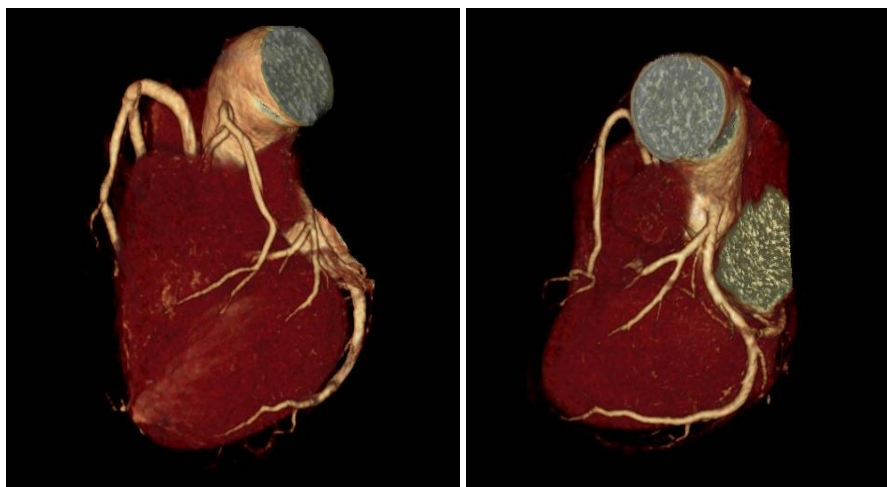


Figure 2. A normal right coronary artery and another vessel arising from the origin of the right coronary artery, initially turning toward the left and then downward to the mid and distal parts of the anterior interventricular groove and giving rise to multiple small septal branches.

The findings of coronary angiography were consistent with a double LAD, with the first vessel originating from the left main stem and the other one arising from the origin of the RCA.

The patient then underwent coronary multidetector computed tomography (MDCT) angiography for further elucidation of the origin and course of the LAD. MDCT was performed using multi-slice 64-detector CT angiography. Volume-rendering image from

the anterior view demonstrated a short LAD arising from the left main coronary artery, moving toward the anterior wall of the left ventricle, and terminating immediately at the initial part of the interventricular groove. It also showed another LAD arising from the origin of the RCA, traveling downwardly along the rest of the interventricular groove, and supplying it with other septal branches. These data confirmed the coronary angiographic findings (Fig. 3 and 4).



Figures 3 and 4. A short left anterior descending artery arising from the left main coronary artery, traveling to the anterior wall of the left ventricle, and terminating immediately at the initial part of the interventricular groove. There is also another left anterior descending artery arising from the origin of the right coronary artery, traveling downwardly to the rest of the interventricular groove, and supplying it with other septal branches.

DISCUSSION

Variations in origin, course, and distribution are rare in both RCA and LCA. Nevertheless, they are rarer in the LCA than in the RCA.⁹ A double LAD is a congenital coronary artery anomaly consisting of an early branching of the proximal LAD—the so-called “LAD proper”—into 2 vessels. One of them is very short, runs always on the anterior interventricular groove, and does not reach the apex: it is termed “the short LAD”. The other one is termed “the long LAD”: it first passes along the anterior interventricular groove, courses following different pathways,

and finally returns to the anterior interventricular groove and reaches the apex. There is also a variation which consists of a long LAD that arises from the RCA or the right sinus and a short one arising from the left main stem.¹⁰

This anomaly is classified into 4 types. Types 1–3 are similar in early bifurcation and the short LAD course, which passes within the anterior interventricular groove and does not reach the apex. The difference is in the long LAD course, which passes along the anterior interventricular groove at the proximal portion, courses through different pathways, and descends on the left side of the anterior

interventricular groove, right side of the anterior interventricular groove, and intramyocardially in the ventricular septum: it is classified as type 1 or 2 or 3—respectively—and finally returns to the distal anterior interventricular groove. In type 4, there are 2 separate vessels containing a very short LAD arising from the left main coronary artery and a long LAD originating from the RCA or the right sinus.

We herein described a patient with a double LAD, which is an extremely rare congenital coronary anomaly. The recognition of the presence of an extra LAD has a significant role in diagnostic and therapeutic purposes. Routine coronary angiography may lead to an incorrect diagnosis of the total occlusion of the proximal part of the LAD when failing to be engaged selectively to an LAD with separate ostia from the right sinus. It is doubtful when the area that is normally perfused by the mid and distal portions of the LAD is avascular and free of collaterals without any retrograde filling of the anomalous LAD. In order to avoid unexpected ligation of the extra LAD at the time of surgery, the cardiac surgeon should be aware of the presence of a double LAD anatomy.¹¹

In conclusion, if there is an LAD which terminates early in the proximal part of the anterior interventricular groove and there is no evidence of total occlusion like the collateral circulation, this anomaly should be considered and search should be continued to find another LAD during selective RCA angiography.

Conflict of Interest: None.

REFERENCES

1. Taylor AJ, Virmani R. Coronary artery anomalies in adults: which are high risk? *ACC Curr J Rev.* 2001;10:92–95.
2. Yamanaka O, Hobbs RE. Coronary artery anomalies in 126,596 patients undergoing coronary

arteriography. *Cathet Cardiovasc Diagn* 1990;21:28–40.

3. Angelini P, Velasco JA, Flamm S. Coronary anomalies. Incidence, pathophysiology, and clinical relevance. *Circulation* 2002;105:2449–2454.
4. Cohen LS, Shaw LD. Fatal myocardial infarction in an 11-year-old boy associated with a unique coronary anomaly. *Am J Cardiol.* 1967; 19(3):420–423.
5. Frescura C, Basso C, Thiene G, Corrado D, Pennelli T, Angelini A, Daliento L. Anomalous origin of coronary arteries and risk of sudden death: a study based on an autopsy population of congenital heart disease. *Hum Pathol.* 1998; 29:689–695.
6. Taylor AJ, Rogan KM, Virmani R. Sudden cardiac death associated with isolated congenital coronary artery anomalies. *J Am Coll Cardiol.* 1992; 20:640–647.
7. Turhan H, Atak R, Erbay AR, Senen K, Yetkin E. Double left anterior descending coronary artery arising from the left and right coronary arteries: a rare congenital coronary artery anomaly. *Heart vessels* 2004;19:196-8.
8. Kosar F. An unusual case of double anterior descending artery originating from the left and right coronary arteries. *Heart Vessels* 2006;21:385–7.
9. Baltaxe HA, Wixson D. The incidence of congenital anomalies of the coronary arteries in the adult population. *Radiology* 1977; 122:47-52.
10. Spindola-Franco H, Grose R, Solomon N. Dual left anterior descending coronary artery: angiographic description of important variants and surgical implications. *Am Heart J* 1983;105:445–55.
11. Tuncer C, Batyraliev B, Yilmaz R, Gokce M, Eryonucu B, Koroglu S. Origin and Distribution Anomalies of the Left Anterior Descending Artery in 70,850 Adult Patients: Multicenter Data Collection. *Cathet Cardiovasc Interven* 2006;68:574–585.